

REVIEW

Emesis in dogs: a review

Emesis is a common presenting sign in small animal practice. It requires a rational approach to management that is based upon a sound understanding of pathophysiology combined with logical decision making. This review, which assesses the weight of available evidence, outlines the physiology of the vomiting reflex, causes of emesis, the consequences of emesis and the approach to clinical management of the vomiting dog. The applicability of diagnostic testing modalities and the merit of traditional approaches to management, such as dietary changes, are discussed. The role and usefulness of both traditional and novel anti-emetic drugs is examined, including in specific circumstances such as following cytotoxic drug treatment. The review also examines areas in which common clinical practice is not necessarily supported by objective evidence and, as such, highlights questions worthy of further clinical research.

C. ELWOOD, P. DEVAUCHELLE*, J. ELLIOTT†, V. FREICHE‡, A. J. GERMAN§, M. GUALTIERI¶, E. HALL||, E. DEN HERTOOG**, R. NEIGER††, D. PEETERS‡‡, X. ROURA§§ AND K. SAVARY-BATAILLE¶¶

Journal of Small Animal Practice (2009) **50**, 000–000
DOI: 10.1111/j.1748-5827.2009.00820.x

Accepted: 9 June 2009

Davies Veterinary Specialists, Manor Farm Business Park, Higham Gobion, Hitchin, Hertfordshire SG5 3HR

*Centre de Cancérologie Vétérinaire, ENVA, 7 Avenue du Général du Galle, 94700 Maisons Alfort, France

†Royal Veterinary College, Royal College Street, London NW1 0TU

‡Clinique Vétérinaire Alliance, 8 boulevard Godard, 33300 Bordeaux, France

§Department of Veterinary Clinical Sciences, University of Liverpool, Leahurst Campus, Chester High Road, Neston, Wirral CH64 7TE

¶Department of Veterinary Clinical Science, Section of Surgery, University of Milan, Via Celoria, 10, 20133 Milan, Italy

||Division of Companion Animal Studies, Department of Clinical Veterinary Science, University of Bristol, Langford House, Langford, Bristol BS40 5DU

**Dierenarts Specialisten Amsterdam, Weesperzijde 147, 1091 ET Amsterdam, The Netherlands

††Universität Giessen, Veterinärmedizinische Fakultät, Medizinische und Gerichtliche Veterinärklinik I, Franfurterstrasse 126, 35392 Giessen, Germany

‡‡Université de Liège, Faculté de Médecine Vétérinaire, Clinique Médicale des Petits Animaux, Bat 44, Sart-Tilman, 4000 Liège, Belgium

§§Servei de Medicina Interna, Hospital Clínic Veterinari, Facultat de Veterinària, Universitat Autònoma de Barcelona, Bellaterra 08193, Spain

¶¶PFIZER Animal Health, Europe & AfME ahg, 23-25, avenue du Dr Lannelongue, 75668 Paris Cedex 14, France

Journal of Small Animal Practice • Vol 50 • xxxx 2009 • © 2009 British Small Animal Veterinary Association

INTRODUCTION

In October 2006, after a series of meetings, the authors published 'Approach to the Management of Emesis in Dogs' (Devauchelle and others 2006), intended as a clinical guide to 'best practice' in the management of canine emesis. Statements in these guidelines were developed from published papers, consensus opinion and, where necessary, the authors' own expert opinions. This review details the evidence and emphasises the opinion from which the guidelines were developed and, by doing so, highlights where evidence is lacking or contradictory.

METHODS

A systematic search of the literature was performed on the sites Google Scholar, Web of Science and PubMed, using the terms 'vomit*' or 'emesis' AND 'dog' or 'canine' to identify relevant references. Where primary sources were available (papers published in peer reviewed journals) these are referenced. Where relevant information did not fit the above search terms (e.g. secondary effects of drugs), references were identified in a standard manner. To further quantify the strength of evidence available to support the information provided, individual references used to support statements were classified according to the scheme shown in Table 1a and assigned an evidence level (EL). As appropriate to support the text an overall evidence grade (OEG) was given according to the scheme in Table 1b. Where multiple references were available, we attempted to ensure those with the highest evidence level were cited. Where peer-reviewed sources were lacking, statements should be considered the opinion of the authors.

THE EMETIC REFLEX

Emesis is facilitated by a sequence of programmed overlapping and coordinated events which reduce the risks of adverse consequences (such as aspiration of acid stomach contents) whilst achieving elimination. The reflex is controlled within the brainstem by a central pattern generator,

Table 1. Scheme used to grade (a) individual references and (b) overall level of evidence. Adapted from 1

(a) Study type	Level of evidence (LOE)
Systematic review (with homogeneity) of randomised controlled clinical trials (RCT)	1a
Individual RCT (with narrow confidence interval)	1b
All or none	1c
Systematic review (with homogeneity) of cohort studies	2a
Individual cohort study (including low quality RCT; for e. g., <80% follow-up) or well-controlled laboratory study	2b
"Outcomes" Research; Ecological studies	2c
Systematic review (with homogeneity) of case-control studies	3a
Individual case-control study or weak laboratory study	3b
Case-series >50 cases	4a
Case series 20 to 50 cases	4b
Case series <20 cases	4c
Expert opinion without explicit critical appraisal, or based on physiology, bench research or "first principles"	5

(b) Types of study	Overall evidence grade (OEG)
Consistent RCT, cohort study, all or none*, decision rule validated in different populations.	A
Consistent retrospective cohort, exploratory cohort, ecological study, outcomes research, good laboratory study, case-control study; or extrapolations from level A studies.	B
Case-series study or extrapolations from level B studies.	C
Expert opinion without explicit critical appraisal, or based on physiology, bench research or first principles.	D

*The all or none principle is met when all patients died before the treatment became available, but some now survive on it; or when some patients died before the treatment became available, but none now die on it

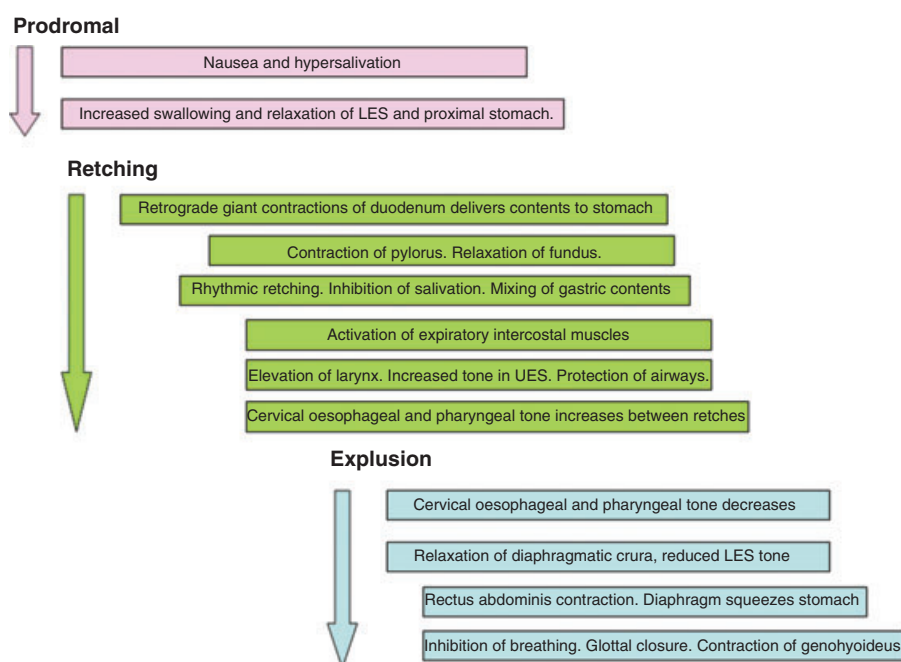


FIG 1. A diagrammatic representation of the series of events comprising the emetic reflex in the dog. LES: Lower oesophageal sphincter. UES: Upper oesophageal sphincter. Summarised from: (Abe and others 1993 [2b], Abe and others 1994 [2b], Furukawa and Okada 1994 [2b], Koga and others 1998 [2b], Koga and Fukuda 1990 [2b], Lang and others 1986b [2b], Lang and others 1986a [2b], Lang and others 1993 [2b], Lang and others 2002 [2b], Onishi and others 2007 [2b], Sha and others 1996 [2b]). [OEG C.]

loosely termed the 'vomiting centre', located in the area dorsomedial to the retrofacial nucleus which initiates a co-ordinated stimulation and inhibition of relevant motor nuclei (Fukuda and Koga 1991 [2b], Fukuda and Koga 1992 [2b], Koga and others 1998 [2b]). Direct projections from this region to motor nuclei such as the caudal part of the ventral respiratory group have been identified (Koga and Fukuda 1997 [2b]). The reflex has visible phases of hypersalivation, retching and expulsion (Figure 1). Efferent pathways controlling these processes include the vagal and phrenic nerves, parasympathetic nerves to the salivary glands and somatic motor nerves to abdominal muscles [OEG B].

CAUSES OF EMESIS

Experimental studies show that many peripheral stimuli of abdominal structures will initiate emesis in dogs (Lang and Marvig 1989 [2b], Xu and Chen 2008 [2b]). Release of 5-hydroxytryptamine/serotonin (5-HT) from enterochromaffin cells, which have been demonstrated in canine gastric and duodenal mucosa, stimulates vagal afferents via 5-HT₃ receptors (Fukui and others 1992 [2b], Fukui and others 1993a [2b]). It seems that other pathways and local modulatory signals are also important (Lang and others 1988 [2b], Sanger and Andrews 2006 [3a]). Peripheral emetogenic triggers may be abrogated by bilateral vagotomy, effects which are enhanced when combined with ablation of the greater splanchnic nerves, suggesting more than one signal pathway (Fukui and others 1993b [2b]). Vagal afferents, carrying peripheral emetogenic signals, enter the rostral medulla oblongata and pass via the solitary tract to the nucleus of the solitary tract (Fukuda and Koga 1991 [2b], Koga and Fukuda 1992 [2b]). [OEG B].

The 'chemoreceptor trigger zone' of the brainstem has been identified as the area postrema which is located on the dorsal surface of the medulla oblongata adjacent to the caudal end of the fourth ventricle (Chernicky and others 1980 [2b]). This region, lacking a blood-brain barrier, is responsive to circulating emetogens. A

number of receptor types have been noted in the area postrema of the dog including dopamine (Stafanini and Clement-Cormier 1981 [2b]), histamine (Bhargava and others 1976 [2b]) and peptide YY (Leslie and others 1988 [2b]). Numerous chemicals, that can induce emesis when administered systemically, also do so via direct application to the area postrema. These include apomorphine, xylazine, prostaglandins and various hormones and peptides (Briggs and Carpenter 1986 [3b], Carpenter and others 1983 [3b], Carpenter and others 1988 [2b], Carpenter and Briggs 1986 [2b], Hikasa and others 1987 [2b]). Ablation of the area postrema inhibits the emetogenic effects of these substances (Carpenter and Briggs 1986 [2b]). Emetogenic signals from the area postrema excite neurones of the nucleus of the solitary tract in the area subpostrema and, from there, the central pattern generator of the vomiting reflex (Koga and Fukuda 1992 [2b]). [OEG B].

Whilst it is generally accepted that dogs, like humans, can suffer motion sickness which can be therapeutically managed, mechanisms are poorly understood and little studied (Conder and others 2008 [1b], Benchaoui and others 2007 [1b], Boyd 1953 [5]). Ablation of the area postrema was thought to stop emetogenic responses to motion, but later critique suggested that a lack of specificity in ablation may have damaged associated structures, possibly the nucleus of the solitary tract, which modulated emetic signals from the inner ear (Borison 1985 [5], Wang and Chinn 1954 [5]). [OEG for mechanisms D].

As well as inputs from peripheral, vestibular and area postrema triggers, stimulation from higher centres has been proposed, presumably co-ordinated in the nucleus tractus solitarius.

Clinical diseases associated with emesis in dogs are summarised (Tables 2-5). In many of these diseases emesis is triggered peripherally and co-ordinated centrally, although there may be concomitant activation of the chemoreceptor trigger zone in some conditions e.g. uraemia. Whilst generally considered a mechanism of protection, vomiting of food by bitches is believed to be part of the normal rearing process (Korda 1972 [3b]) [OEG C].

Table 2. Gastrointestinal disease conditions associated with emesis in the dog

	Process	Reference (LOE)	Overall evidence grade		
Gastritis	Eosinophilic	2 (4c)	C		
	Lymphoplasmacytic	3 (4c)			
	Granulomatous	4(4c)			
	Acute	5(4c)			
		6 (4a)			
	Associated with spiral bacteria	7 (3a)			
Gastric neoplasia		8 (4b)	C		
		9 (4b)			
		10 (4b)			
		6 (4a)			
Gastric ulceration	Non-steroidal anti-inflammatory drugs (NSAIDs)	11 (4b)	B		
		12 (4c)			
		13 (3b)			
	Neoplasia	14 (4c)			
		15 (4c)			
		10 (4b)			
	Metabolic	11 (4b)			
		16 (4b)			
		17 (4c)			
		18 (4c)			
Gastric/intestinal entrapment	Hypergastrinaemia/Other APUDomas	19 (4c)	D		
	Irritant				
	Mastocytosis	20 (4c)			
	Ruptured diaphragm	21 (4b)			
	Gastric dilatation/volvulus				
	Hiatal hernia	22 (4c)			
		23 (4c)			
	Pyloric stenosis	Congenital		24 (4c)	C
				25 (4b)	
				26 (4c)	
Chronic hypertrophic pyloric gastropathy		27 (4c)			
Foreign body		28 (4c)	C		
		29 (4a)			
		30 (4c)			
Dietary		31 (4c)	C		
		32 (4b)			
		33 (4c)			
Infection/Infestation	Canine parvovirus	34 (1b)	A		
		35 (1b)			
	Canine distemper virus				
	Canine coronavirus	36 (4c)			
	Salmonellosis	37 (4b)			
	Campylobacteriosis	38 (4c)			
	Mycobacterial infection	39 (4c)			
	Fungal infection	40 (4c)			
		41 (4c)			
		42 (4a)			
Inflammatory bowel diseases	Hookworms/Roundworms	43 (4c)	C		
	Eosinophilic	44 (4a)			
	Lymphoplasmacytic Granulomatous				

(Continued overleaf)

Table 2. Continued

Intestinal neoplasia		45 (4b)	C
		46 (4c)	
		47 (4b)	
		48 (4c)	
Intussusception		49 (4b)	C
Intestinal volvulus		50 (4c)	C
		51 (4c)	
Intestinal entrapment		52 (4c)	C
Motility disorders	Dysautonomia	53 (4a)	C
		54 (4c)	
	Localised autonomic dysfunction	55 (4c)	C
		56 (4c)	
		57 (4c)	
		58 (4c)	

CONSEQUENCES AND COMPLICATIONS OF EMESIS

Emesis is associated with signs of nausea (e.g. depression, salivation, lip licking, increased swallowing motions) and loss of appetite. Whilst, in most clinical situations, the consequences of the disease process *per se* and of emesis cannot be completely distinguished, persistent and severe emesis leads to loss of gastrointestinal fluid and electrolytes, with consequent dehydration, hypovolaemic shock, acid-base and electrolyte disturbances (e.g. metabolic acidosis/alkalosis, hypokalaemia) which can be life-threatening (Boag and others 2005 [4a], Cornelius and Rawlings 1981 [4a]). Aspiration pneumonia can occur secondary to vomiting (Kogan and others 2006 [4a]). Persistent vomiting that prevents effective oral intake of food is likely to lead to protein-calorie malnutrition (see 'Dietary management'). These concomitant problems must be assessed and treated appropriately as part of the clinical management of the dog with emesis. [OEG C].

Table 3. Non-gastrointestinal abdominal disease conditions associated with emesis in the dog

	Process	Reference (LOE)	Overall evidence grade
Peritoneal neoplasia		59 (4c)	C
Steatitis		60 (4c)	C
Peritonitis	Septic	61 (4c)	C
		62 (4c)	
	Bile	63 (4c)	C
		64 (4b)	
	Urine		D
	Idiopathic	65 (4c)	C
Hepatobiliary disease	Neoplasia	66 (4c)	C
	Hepatitis/hepatopathy	67 (4a)	
		68 (4c)	
		69 (4b)	
	Infectious	70 (4a)	C
		71 (4b)	
		72 (4b)	
	Immune (?)		D
	Toxic		C
Cholangiohepatitis/ Cholangitis/Cholelithiasis		76 (4c)	C
		63 (4c)	
		77 (4c)	
		78 (4c)	C
	79 (4c)	C	
	80 (4c)	C	
Splenic diseases	Torsion	81 (4c)	C
	Abscess	82 (4c)	C
	Infarction	83 (4c)	C
	Neoplasia	84 (4c)	C
Pancreatic diseases	Pancreatitis	85 (4a)	C
	Neoplasia	86 (4c)	C
	Phlegmon	87 (4c)	C
	Pseudocyst	87 (4c)	C
		88 (4c)	
Abscess		C	
Renal diseases	Nephrolithiasis/Abscess	90 (4c)	C
	Neoplasia	91 (4c)	C
Urogenital diseases	Pyometritis	92 (4c)	C
	Endometritis	93 (4c)	C
	Urethrolithiasis	94 (4b)	C

CLINICAL PRESENTATION AND INITIAL ASSESSMENT

Initial assessment of dogs with emesis should evaluate their general health condition (determination of the severity of the disease process) which will differentiate those in which no treatment is necessary, those which need to be treated symptomatically and those which need further examination or specific treatment. In addition the initial assessment may give clear indications of the underlying cause of the vomiting.

The initial assessment starts with the age, breed and gender of the dog. The age is important because some diseases are more common in young dogs, e.g. ingestion of foreign bodies, foreign body induced ileus (Capak and others 2001 [4a]), dietary indiscretion, infectious diseases, intussusception, chronic intestinal pseudo-obstruction (Johnson and others 2007 [4c]), and other diseases e.g. gastric neoplasia, are more common in older dogs (Gualtieri 1996 [4b], Gualtieri and others 1999 [3a], Sautter and Hanlon

Table 4. Systemic disease conditions associated with emesis in the dog

	Process	Reference (LOE)	Overall evidence grade
Metabolic	Uraemia	95 (4c)	C
		96 (4a)	
		97 (4b)	
	Ketoacidosis	98 (4a)	C
	Hepatic encephalopathy		D
	Hypoadrenocorticism	19 (4c)	C
		99 (4b)	
		100 (4a)	
		101 (4c)	
	102 (4a)		
	Hypercalcaemia	103 (4c)	C
	Hypocalcaemia	104 (4c)	C
	Hypocobalaminaemia	105 (4c)	C
Hypokalaemia		D	
Hyper/hyponatraemia		D	
Septicaemia		D	
Hyperviscosity	106 (4c)	C	
Toxic	Lead	107 (4b)	C
	Ethylene glycol	108 (4b)	C
	Ethanol	109 (4c)	C
	Theobromine	110 (5)	D
	Apomorphine	111 (1b)	A
		112 (1b)	
		113 (1b)	
114 (1b)			
Many others		D	
Drug induced	Chemotherapeutics e.g. cisplatin, methotrexate	115 (4b)	A
		116 (1b)	
		117 (1b)	
		118 (4b)	
		119 (1b)	
	Digoxin	120 (1b)	A
		121 (4c)	
	Erythromycin	122 (1b)	A
		123 (1b)	
		124 (1b)	
125 (1b)			
Many others			

Table 5. Nervous system disease conditions associated with emesis in the dog

	Reference (LOE)	Overall evidence grade
Trauma		D
Hydrocephalus		D
Space-occupying lesion	126 (4c)	C
	127 (4c)	
Meningitis		D
Encephalitis		D
Motion sickness	128 (1b)	B
	129 (1b)	
	130 (2b)	
Vestibular disease		D
Cerebellar disease		D
Visceral epilepsy		D
Sialadenosis(?)	131 (4c)	C

1975 [4b]). Breed is an important consideration; Belgian shepherd dogs have a breed predisposition for gastric carcinoma (Scanziani and others 1991 [4c]), chronic hypertrophic pyloric gastropathy is seen more often in certain toy breeds (Bellenger and others 1990 [4c], Walter and others 1985 [4c]), and hypoadrenocorticism in the Nova Scotia Duck tolling retriever (Hughes and others 2007 [4b]). There are many more breed predilections that can be mentioned. Some diseases also have a gender predilection e.g. hypoadrenocorticism is more commonly seen in female dogs (Kintzer and Peterson 1997 [3a]) and some diseases exclusively affect one gender (e.g. pyometra, prostatitis).

A full and complete history is essential for evaluation of a vomiting dog. Information which should be obtained is listed (Table 6). The most important distinction is that between vomiting and regurgitation, because their aetiology is very different and this will direct specific diagnostic testing. Regurgitation is passive, with undigested food or saliva returned under gravity, whereas vomiting is a reflex, accompanied by signs of nausea, hypersalivation and activity of the abdominal musculature.

A thorough physical examination is required and should include assessment of features shown (Table 7). From the signalment, history and physical examination, the clinician should be able to identify criteria for concern which might indicate a need for immediate diagnostics investigation and/or therapy (Table 8). [OEG C].

DIAGNOSTIC APPROACH

The misnomer 'acute gastritis' is commonly used to describe a syndrome of acute and self limiting emesis. In almost all of these cases, however, gastric inflammation is not proven by histopathology. Gastritis is a frequently cited yet rarely confirmed diagnosis in cases of canine anorexia and emesis. Dogs with simple, mild, acute self limiting emesis do not need further work-up, and can be treated symptomatically. Many of these animals are not seriously ill, and may need no treatment. A recent study suggests 95% of dogs with emesis do not present to the veterinary surgeon (Hubbard and others 2007 [4a]). Even in

Table 6. History taking for the dog with emesis

A thorough history should be obtained during the initial assessment, including the following:	Example demonstrating the importance of this information	Reference (LOE)	Overall evidence grade
Onset and progression of signs	Sudden onset can suggest ingestion of foreign body or dietary indiscretion	29 (4a)	C
Emesis or regurgitation	Regurgitation is seen in oesophageal disease	132 (4b)	C
Relationship to eating	Vomiting > 10-12 hours after meal indicates delayed gastric emptying (outflow obstruction, motility disorder)	30 (4c)	C
The frequency, volume and nature of vomitus, including the presence of any fresh or digested blood	Haematemesis is sometimes seen after use of NSAIDs or acute vomiting	133 (4c) 134 (4b) 85 (4a) 135 (4c) 136 (4c) 137 (4c) 138 (4c)	C
Whether or not there is any diarrhoea	Diarrhoea may suggest concurrent intestinal disease, but can be seen with other conditions e.g. pancreatitis	139 (4b) 140 (2a) 85 (4a) 141 (4c) 142 (4c) 143 (4a)	C
Presence and progression of weight loss	Weight loss suggests chronic disease, e.g. gastro-intestinal tumour	144 (4a)	C
Appetite and ability to maintain nutritional status	Early enteral nutrition is important in recovery	145 (3b)	B
Fluid intake (increased, decreased or normal)	Polydipsia is seen with pyometritis	146 (4a)	C
Presence and nature of any abdominal pain	Abdominal pain can e.g. be seen in pancreatitis	85 (4b)	C
Recent changes in diet or provocative changes, including recent or ongoing drug treatment and access to toxins or foreign bodies	Emesis can be seen as a side effect of many drugs.	147 (4c) 148 (4b) 149 (4c) 150 (1b) 151 (4b)	A
	Change in diet can cause vomiting		D
	Severe exercise can cause gastritis.	152 (4c)	C
	Intoxication can cause vomiting e.g. ethylene glycol, grapes, <i>Bufo marinus</i>	108 (4b) 97 (4b) 153 (4a)	C
	Ingestion of foreign body is a cause of emesis	29 (4a)	C
	Vaginal discharge can be seen in pyometritis	146 (4a) 154 (4a)	C
Reproductive status including recent seasons and presence of any vaginal discharge	Information on the reproductive status can suggest mucometra or closed cervix pyometra	155 (4b) 156 (4c)	C
	Co-existing neurological signs suggest neurologic disease	55 (4c) 53 (4a) 157 (4c) 126 (4b)	C
Presence of neurological signs e.g. head tilt, ataxia, nystagmus, altered behaviour or consciousness	Emesis associated with motion sickness	128 (4c)	B
	Urinary tract disorders can be associated with emesis	158 (4b) 159 (4c)	C
Presence of other signs suggestive of a systemic disease e.g. urinary tract signs (dysuria etc)			

those that present to a veterinary surgeon, in most cases of acute self limiting emesis, the aetiology is never determined: diet-related factors (dietary indiscretion), infectious agents and toxins are considered the most important causes. If the signs resolve after 1 to 2 days, with or without symptomatic and supportive therapy, the tentative diagnosis of acute self limiting emesis is considered correct.

In those cases where further investigation is considered necessary a variety of diagnostic tests may be indicated (Table 9). [OEG D]

TREATMENT

A number of potential adverse effects of persistent emesis have already been

detailed. Treatment of persistent emesis reduces suffering and prevents complications whilst a thorough investigation is undertaken to identify and, where possible, treat the underlying cause.

The decision to treat emesis or to wait and see if the problem resolves will depend on the circumstances in each individual case where the risk-benefit analysis of using a drug to prevent further emesis

Table 7. Important considerations in the physical examination of the dog with emesis

Physical examination of the vomiting dog should include assessment of:	Example demonstrating the importance of this information	Reference (LOE)	Overall evidence grade
Cardiovascular and hydration status, including mucous membrane colour, capillary refill time, heart and pulse rate, rhythm and strength	Fluid therapy should be started in a dehydrated dog Bradycardia can be seen in hypoadrenocorticism.	160 (4a) 99 (4b) 100 (4a)	C
Body temperature	Fever can be an indicator of infectious or inflammatory diseases	34 (1b) 35 (1b)	A
Peripheral lymph nodes assessment	Gastrointestinal lymphoma can be associated with multicentric lymphoma	45 (4c) 161 (4c)	C
Skin examination	Cutaneous mast cell tumour can cause emesis	162 (4c)	C
Presence of halitosis	Halitosis can be an indicator for the presence of necrosis in the oral cavity, pharynx or oesophagus, e.g. due to a foreign body or necrosis of the salivary gland	163 (4c) 164 (4c) 165 (4b)	C
Body condition	Weight loss suggests chronic disease, e.g. small intestinal tumour	144 (4a)	C
Presence and localisation of abdominal pain, masses and foreign bodies	Abdominal pain can be seen in e.g. pancreatitis An abdominal mass can be the cause of the emesis	91 (4c) 85 (4a) 166 (4c) 161 (4c)	C
Presence of free abdominal fluid	Peritonitis can cause emesis Ascites can be seen in portal hypertension	167 (4c) 168 (4b)	C
Presence and nature of any vaginal discharge	Vaginal discharge can be seen in bitches with pyometritis	154 (4a)	C
Oral cavity examination	Presence of foreign bodies (including under the base of the tongue)	169 (4c)	C

needs to be assessed (Hubbard and others 2007 [4a]). These authors showed that in 89% of dogs with signs of vomiting, signs resolved in less than two days. The clinician should judge the need for further investigation and treatment; a suggested approach is summarized in the algorithm (Figure 2). Emesis may be a desirable outcome following toxic ingestion, and antiemetics, especially where there is also a pro-kinetic effect, are not indicated where there is gastrointestinal obstruction. To minimise the risk of anti-emetics masking significant clinical signs it is important to initially identify those cases requiring further investigation and to ensure effective follow-up examinations are planned to reassess the progress of cases that are treated symptomatically. A risk benefit assessment should be made of the likely success of a particular drug in preventing and treating emesis versus the likelihood of the drug inducing adverse effects.

If the veterinarian considers initial treatment unnecessary or institutes non-specific, symptomatic management for suspected acute self-limiting vomiting, pet owners should be advised that, following initial assessment, there is no immediate need for a more specific diagnosis or treatment and that non-specific therapy is sufficient in many cases (Hubbard and others

2007 [4a]). They should be advised of the benefits and effects of therapy and of what outcome measures to monitor (see 'Monitoring' below). The use of an antiemetic drug should not delay any necessary investigation or treatment if deemed necessary by the clinician. Supportive care of the patient with emesis may include fluid and electrolyte therapy to correct or prevent dehydration and/or electrolyte and acid-base therapy. Though treating the symptom itself will often improve patient demeanour and comfort, it is no replacement for making a correct diagnosis. [OEG D].

The ideal antiemetic

Antiemetics are used symptomatically to manage a clinical manifestation of a wide spectrum of different diseases. In many clinical situations e.g. uraemia, emesis may occur because of a combination of stimuli (central and peripheral). The relative importance of the different pathways may or may not be apparent from the clinical presentation or diagnosis. The ideal drug will, therefore, prevent both central and peripheral stimuli of the 'vomiting centre' (see section 'Causes of vomiting'). In addition, because persistent and/or severe emesis can result in significant fluid loss and electrolyte disturbances, the ideal antiemetic drug should be without effect

on the cardiovascular system since actions here can upset the delicate haemodynamic balance in a dehydrated patient. Furthermore, a drug with a very wide therapeutic index would be desirable, particularly as emesis can be associated with kidney and liver disease, two major organ systems involved in the clearance of drugs from the body. Drugs with narrow therapeutic indices would be unsafe to administer to dogs with significant kidney or liver dysfunction. In addition central nervous system side-effects, such as sedation, might be undesirable in drugs used treat emesis because changes in central nervous system (CNS) function may make diagnosis of the underlying cause of the emesis or assessment of the progression of the dog's condition difficult and, potentially, predispose to adverse events such as aspiration. Finally, a lack of direct effects of an antiemetic on GI motility would be desirable in most cases, although a prokinetic effect may be beneficial in some conditions such as chronic gastritis.

It should be recognised that, because of the multiple inputs into the vomiting centre, the involvement of co-transmitters within a given pathway and the facilitatory actions of a number of neurotransmitters on each pathway, the holy grail of identifying one drug that inhibits all

Table 8. Criteria for concern in vomiting dogs

A number of findings on initial consultation and examination might indicate a need for further investigation including:	Example demonstrating the importance of this information	Reference (LOE)	Overall evidence grade
Very frequent acute emesis, vomiting large volumes (especially if food has been withheld), vomiting contents of a foetid nature	Can be a sign of ileus, needing surgical intervention and symptomatic treatment	58 (4c) 170 (4a)	C
Chronicity (>3-4 weeks)	Chronic emesis can indicate a not self limiting chronic gastrointestinal disease, which need specific diagnosis and treatment	46 (4c) 171 (4c) 3 (4c) 44 (4a) 45 (4b)	C
Marked weight loss/failure to thrive	Marked weight loss is seen in dogs with neoplasia or chronic small intestinal disease.	105 (4c) 44 (4a) 45 (4b)	C
Marked malaise	Significant malaise is rarely seen in trivial disease.		D
Marked abdominal pain	Can indicate significant disease e.g. peritonitis, pancreatitis	14 (4c) 142 (4a)	C
Haematemesis and/or melaena	Suggests gastro-intestinal ulceration or neoplasia	172 (4c) 134 (4a) 173 (4a)	C
Abdominal swelling/free fluid/palpable abdominal mass	Protein losing enteropathy can lead to hypoalbuminaemia and subsequent ascites Abdominal masses always warrant further examination	174 (4b) 175 (4a) 176 (4c) 177 (4c) 178 (4c)	C
Fever	Might indicate peritonitis or other inflammatory/infectious disease	63 (4b) 179 (4b)	C
Associated polyuria/polydipsia	Seen with pyometra, kidney failure, hypercalcaemia and hypoadrenocorticism	96 (4a) 85 (4a) 103 (4c) 102 (4b)	C
Severe dehydration/hypovolaemia/shock	Needs fluid therapy	99 (4b)	C
Bradycardia (absolute or relative to volume status)	Seen in hypoadrenocorticism	100 (4a) 102 (4b)	C
Other abnormal physical examination findings e.g., pale mucous membranes, jaundice, neurological signs, cardiac dysrhythmias etc.	Pale mucous membranes and jaundice can be signs of haemolytic anaemia Jaundice is seen in hepatobiliary diseases Severe dermatologic signs together with emesis can indicate specific diseases	180 (4c) 77 (4c) 181 (4c) 46 (4c) 182 (4b) 183 (4c)	C
Persistence of emesis despite symptomatic therapy	Needs further work up	184 (4a)	C

causes of emesis and nausea is never likely to be achieved. Figure 3 outlines the antiemetic drug target receptor distribution in relation to different arms of the vomiting reflex and Table 10 summarizes the properties of currently available antiemetic drug classes in veterinary medicine and the evidence for their usefulness in dogs, helping the clinician to select the drug whose profile best suits the individual patient.

Antiemetic treatment in practice

Most of the studies used to provide evidence for the statements made in table 10 are from experiments where the dog has been used as a model and emesis has been induced to determine the antiemetic's efficacy. In clinical practice across Europe, a

number of antiemetics may be used, such as metoclopramide (orally or by infusion), domperidone, ondansetron and acepromazine. Many of these drugs are in routine clinical use and are generally considered to be effective and useful, but few have been subjected to rigorous testing and there is a dearth of clinical evidence to support the efficacy of many of these antiemetic drugs under field conditions. A systematic search of the literature for 'antiemetics AND dogs' (limited to clinical trials) yielded 97 papers, only 5 of which were true clinical trials involving field cases in veterinary practice. Moore and others (1994 [1b]) examined the antiemetic effects of butorphanol and cyproheptadine in clinical cases of lymphoma receiving cisplatin and

demonstrated butorphanol was moderately effective. Valverde and others (2004 [1b]) demonstrated the value of pre-treating with acepromazine in preventing opiate-induced emesis in dogs receiving opiates as part of a pre-anaesthetic protocol. The other three papers involved the neurokinin-1 (NK-1) receptor antagonist, maropitant. De La Puente-Redondo and others (2007a [1b]) conducted a clinical trial examining the ability of antiemetic drugs to arrest emesis due to medical conditions in dogs under field conditions. In both phases maropitant performed significantly better than metoclopramide, both in terms of a lower proportion of dogs that vomited after administration of the antiemetic and the number of emetic events

Table 9. Diagnostic tests used in the investigation of dogs with emesis

Diagnostic test	Indication	Information that is intended to be obtained	Reference (LOE)	Overall evidence grade
Complete blood count	Criteria of concern (table 5)	Dehydration Hemoconcentration Leucopenia Polycythaemia Anaemia Microcytosis Eosinophilia	100 (4a) 185 (4c) 186 (4b)	C
Total protein, albumin	Diarrhoea, ascites	Hypoproteinaemia	175 (4a)	C
Liver enzymes, bile acids	Jaundice, chronic emesis	Hepatobiliary disease	168 (4b) 63 (4b) 77 (4c) 69 (4b)	C
Blood glucose	Diarrhoea in toy breeds, seizures	Hypoglycaemia	187 (5)	D
Calcium	Polyuria/polydipsia	Hypercalcaemia Hypocalcaemia	100 (4a) 102 (4b) 103 (4c)	C
Pancreatic enzymes, cPLI	Abdominal pain	Pancreatitis	188 (4b)	C
Adrenocorticotrophic hormone (ACTH) stimulation test	Bradycardia, hyperkalemia, dehydration, polyuria, weakness, lack of stress leukogram, hypocholesterolaemia	Hypoadrenocorticism	100 (4a) 102 (4b) 189 (4b) 19 (4c)	C
Coombs' test	Pale mucous membranes, jaundice	Immune-mediated haemolytic anaemia	186 (4b)	C
Lipid profile	Parvoviral enteritis	Prognostic factor	190 (3b)	B
Electrolytes	Dehydration, dysrhythmias, bradycardia, fluid therapy	Electrolyte disturbances that need correction by fluid therapy Changes of hypoadrenocorticism	100 (4a) 102 (4b) 160 (4a)	C
Culture of bile	Liver enzyme activity increases, abnormal gall bladder or gall bladder content on ultrasound	Bacterial cholecystitis	183 (4c) 77 (4c)	C
Ultrasonography	Abdominal mass, increases in liver enzyme activity, free fluid in abdomen	Hepatobiliary disease Foreign bodies Neoplasia, Urinary tract disorders Muco-/pyometra Pancreatitis	77 (4c) 156 (4c) 158 (4c) 85 (4a) 79 (4c), 159 (4c), 31 (4c) 180 (4c), 191 (4b)	C
Radiography	Very frequent acute vomiting, vomiting large volumes (especially if food has been withheld), vomiting contents of a foetid nature	Foreign body Gastric position and size Peritonitis Ileus Intestinal entrapment	192 (4c) 52 (4c) 85 (4a) 193 (4c) 31 (4c) 191 (4b)	C
Electrocardiography	Dysrhythmias, bradycardia	Hyperkalaemia	100 (4a) 102 (4b)	C
Computed tomography	Abdominal organomegaly, focal pain	Evaluation of abdominal organs	194 (4c) 87 (4c)	C
Magnetic resonance imaging	Abdominal organomegaly, focal pain Neurological signs	Evaluation of abdominal organs Evaluation of CNS disease	195 (4b) 196 (4c) 197 (4c)	C
Liver biopsy	Increases in liver enzyme activity and/or bile acid concentration, abnormal appearance of liver on ultrasound	Hepatobiliary diseases	177 (4c) 69 (4b)	C
Endoscopy	Ingestion of foreign body Chronic emesis and/or diarrhoea	Visualisation of mucosa Gastric and intestinal biopsies	29 (4a) 198 (4b) 44 (4a)	C
Faecal examination	Diarrhoea	Parasitic disease	199 (4a)	C
Urinalysis	Signs of urinary tract disease (dysuria, haematuria)	Urolithiasis, urinary tract inflammation and/or infection	158 (4c) 159 (4c)	C
Parvovirus antigen test	Diarrhoea, haematochezia	Parvoviral enteritis	200 (1b)	A

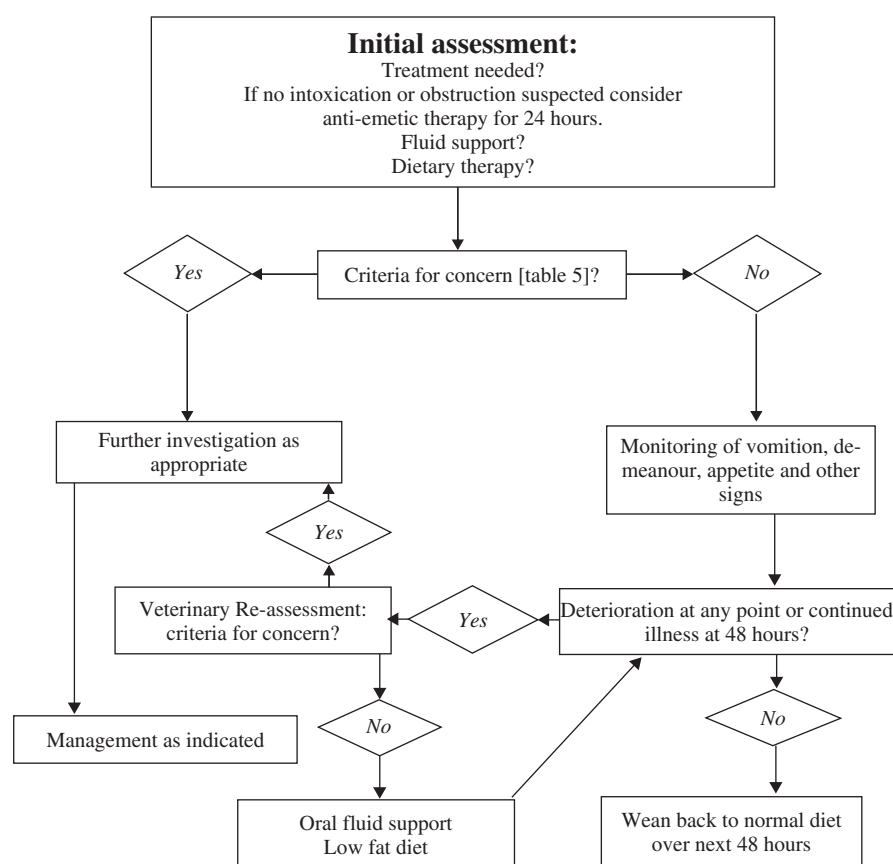


FIG 2. An algorithm to guide the approach to the management of emesis in the dog. If the patient is initially treated symptomatically, re-examinations should be scheduled and the patient re-assessed for criteria of concern (see table 8) that might prompt further investigation. [OEG D]

recorded in those dogs that vomited. Vail and others (2007 [1b]) examined the effect of maropitant on frequency of emesis in clinical patients receiving cisplatin, given at a higher dose than in the study of Moore and others (1994 [1b]), and demonstrated that maropitant prevented emesis and also suggested efficacy to treat and prevent nausea induced by chemotherapy, as evaluated by a visual analogue scale. The final clinical trial also involved maropitant and examined its ability to prevent motion sickness in dogs prone to this problem (Benchaoui and others 2007 [1b]). This was a large multicentre placebo controlled clinical trial which demonstrated that maropitant reduced the number of dogs vomiting on the journey when compared to placebo.

DIETARY MANAGEMENT

There are limited data to advise small animal clinicians on the optimal feeding

strategy for vomiting patients. Two main scenarios should be considered, and will be approached separately. The first is a severely affected vomiting patient where hospitalisation is required; the second is a patient where vomiting is less severe and can be handled as an out-patient.

Vomiting patients requiring hospitalisation

In humans, there is a wealth of information supporting the use of enteral methods of feeding over parenteral nutrition. In a critical review by Zaloga (2006 [1b]), compared with parenteral nutrition (PN), the use of enteral nutrition (EN) improved survival, decreased infection rate, decreased bacterial translocation, enabled earlier discharge from hospital, and was more cost effective. However, a meta-analysis examining the benefits of either enteral nutrition or volitional nutritional support over *nil per os* strategies is more controversial, suggesting that, besides from using volitional nutritional support in ger-

iatric patients, most studies did not demonstrate a clear benefit (Koretz and others 2007 [1a]).

Numerous studies are available which detail the methodology, applications, benefits and complications of both EN (Abood and Buffington 1992 [4a]; Michel and Higgins 2006 [4b]) and PN (Lipfert and others 1993 [4a]; Chandler and Payne-James 2006 [4c]) in dogs. A complete discussion of this information is outside the scope of the current review, but broadly speaking, both techniques can provide benefit to hospitalised in-patients, but are associated with various complications. Most notably vomiting and other alimentary tract signs are a common complication of the enteral method of feeding (Abood and Buffington 1992 [4a]). Thus one potential benefit of controlling nausea and vomiting in companion animals is that it may enable enteral nutrition to be administered at an earlier opportunity and with lower associated morbidity. Data from clinical studies directly comparing EN and PN in dogs with alimentary tract disease are, however, extremely limited.

Experimental studies in dogs

Two experimental studies have assessed the effects of early EN on pancreatic pathological features and gut barrier function in dogs with experimental acute pancreatitis (Qin and others 2002 [2b], Xu and others 2006 [2b]). The conclusion from these studies was that EN is preferred over PN for cases of acute pancreatitis. Clinical studies are, however, recommended to determine applicability in this setting.

Clinical studies in dogs

One randomised, unblinded, clinical study has compared the effect of early enteral nutrition (EEN), versus food withholding, in cases with parvoviral enteritis whose signs included emesis (Mohr and others 2003 [2b]). The EEN group were fed with a standard critical care diet, via naso-oesophageal tube, commencing after 12 hours of hospitalisation; in contrast, food was withheld in the 'nil per os' (NPO) group until emesis had ceased. There was a trend towards improved survival in the EEN group, given that all EEN dogs survived whilst 13/15 NPO did. The EEN group also showed earlier

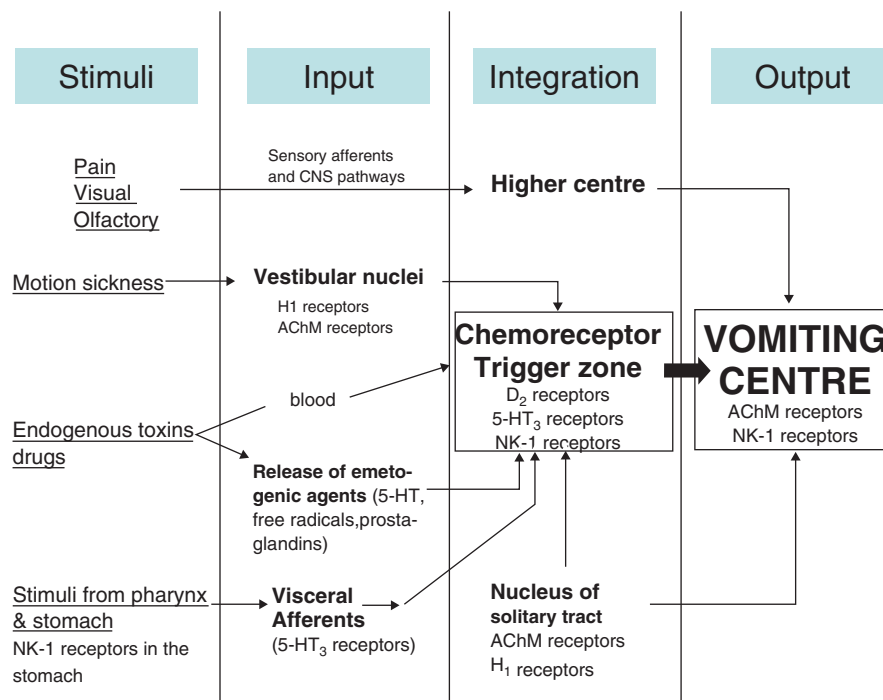


FIG 3. Schematic diagram of the vomiting reflex indicating probable sites of action of antiemetic drugs. Peripheral emetogens (e.g. ipecac) stimulate the pharynx or stomach where Neurokinin-1 receptors are involved in local sensory nerve activation and 5-HT₃ receptors are involved in modulating the activity of visceral afferent nerves which convey the sensory information to the CNS. Stimuli which cause vomiting can also reach the CNS through the blood stream (e.g. toxins – central emetogens; e.g. apomorphine) to stimulate the chemoreceptor trigger zone. Within the central nervous system, inputs are integrated and the relayed to the ‘vomiting centre’ a collection of neurones in the brain stem which are thought to be the origin of the efferent arm of the vomiting reflex. Vomiting is elicited when the integrated inputs exceed the threshold and the motor output from these neurones leads to the co-ordinated action of vomiting

clinical improvement, with more rapid (by 1 day) improvement in demeanour, appetite, vomiting and diarrhoea. Further, significant weight gain occurred in this group, but did not in the NPO group, whilst improved intestinal barrier function was seen.

A similar clinical study has assessed the benefits of combined parenteral and oral nutrition compared with parenteral nutrition alone, in young dogs with haemorrhagic gastroenteritis (Will and others 2005 [2b]). Dogs were alternately allocated to each group, and treated for at least 4 days. In the enteral nutrition group, a ‘hydrolysed’ cottage cheese based diet, pre-incubated with pancreatic enzymes, was administered by syringe from day 2 onwards. Most dogs in the enteral nutrition group vomited within half an hour of starting feeding on the second day, but were able to tolerate food better on subsequent days. There was no significant difference in gen-

eral health status and clinicopathological parameters between groups. However, all 10 dogs in the early enteral nutrition group survived, compared with 7 out of 9 of those in the parenteral nutrition group. Although the study is small, this latter finding in conjunction with the survival data from Mohr and others (2003 [2b]), may suggest a benefit of early enteral feeding in patients with severe gastrointestinal disease. More work would, however, be required to support such an approach.

The remaining publications are either review articles or pertain to single case reports or small case series where nutritional support is employed as a component of therapy for patients with severe gastrointestinal signs (Aroch and others 1997 [4c], Holland 1996 [4c], Young and others 2007 [4c]). Such information suggests that early enteral nutrition is of benefit, but should be interpreted with caution. [OEG C]

Vomiting patients handled as out-patients

In dogs with acute emesis that are systemically well, the most common approach is to withhold food for a period (usually ~24 hours). In contrast, the trend in human gastroenterology is to continue to feed in the face of gastrointestinal signs, and there is now clear evidence that continuation of feeding during gastroenteritis has advantages (Sandhu 2001 [2b]). There are no equivalent published studies assessing the relative merits of food withholding and early feeding in veterinary medicine. Given that the majority of dogs with acute gastrointestinal signs are likely to have self-limiting disease, it is unlikely that there would be a dramatic benefit or detriment for either method. Finally, published data examining what dietary characteristics are most appropriate for acutely vomiting dogs are lacking. In the absence of such information, a highly-digestible diet seems most appropriate. [OEG D].

MONITORING

When symptomatic management is instituted, only the prescribed medications and diet recommended by veterinarian should be administered and an initial limit of 24 hours of any anti-emetic treatment is suggested. Owners should be made aware of the potential of any anti-emetic therapy to mask emesis and should be advised to observe the pet closely and to contact the veterinary surgeon as soon as possible if there are any signs of deterioration and/or the patient is getting worse, with a view to arranging a re-examination. They should be advised to re-present the patient after a maximum of 48 hours if there is continued emesis or if there is no improvement in other outcome measures. Alternative outcome measures include appetite (which may reflect associated nausea), general demeanour, and other associated clinical signs e.g. diarrhoea. It should be stressed that the owners should return more quickly if they are concerned. At re-assessment, the clinician should repeat the initial consultation and re-consider criteria for further treatment and/or investigation as above. [OEG D].

Table 10. Antiemetic drugs in dogs

Drug group and drug doses	Receptor pharmacology	Pathways inhibited	Other actions (including adverse effects)	Side-effects and contra-indications	Reference (LOE)	Overall evidence grade (anti-emetic action)
Phenothiazines Acepromazine: 0.01-0.05 mg/kg i.m., s.c. 1-3 mg/kg p.o. Chlorpromazine: 0.5 mg/kg i.m., s.c. q6-8h	D ₂ and H ₁ receptor antagonist. Anticholinergic and anti-serotonergic actions (weaker)	Central emetogens (anti-D ₂); motion sickness (anti-H ₁)	Alpha ₁ receptor antagonist	Pre-licensing safety studies not performed. Decreases blood pressure in dehydrated animals Anti-cholinergic side effects Movement disorders Sedative actions	201 (3b) 202 (2c) 203 [1b]	B
Butyrophenones Domperidone: 2.5 mg per animal q8h	D ₂ antagonist	Central emetogenic pathway	Alpha ₁ receptor antagonists	Pre-licensing safety studies not performed. Decreases blood pressure in dehydrated animals Sedative actions	117 (2b) 112 (2b)	C
Metoclopramide: 0.2-0.5 mg/kg i.m., s.c., p.o. q6-8h or 1-2 mg/kg i.v. over 24 hours as slow constant rate infusion.	D ₂ antagonist 5-HT ₃ antagonist (weak) H ₁ antagonist (weak)	Central emetogenic pathway (D ₂ antagonism); some action versus peripheral emetogens Some effect vs. motion sickness (weak) At high doses reduces gastro-oesophageal reflux associated with anaesthesia and dopamine-induced inhibition of lower oesophageal sphincter tone	Variable prokinetic effect (peripheral) which may contribute to antiemetic action in some, but not all cases	Pre-licensing safety studies not performed. Increases detrusor muscle contractility reducing bladder capacity Movement disorders Extrapyramidal signs	204 (2b) 205 (1b) 206 (1b) 207 (3b) 117 (2b) 208 (1b) 209 (1b) 210 (2b) 114 (1b) 211 (2b) 212 (2b)	B
Ondansetron: 0.5 mg/kg i.v. loading dose followed by 0.5 mg/kg/h infusion for 6 hours or 0.5-1 mg/kg p.o. q12-24 hours	5-HT ₃ selective antagonists	Works best versus acute peripheral emetogens (e.g. chemical irritants to the gut - cisplatin causing degranulation of enterochromaffin cells and 5-HT release). Also effective vs. radiation induced emesis. Represented a major breakthrough in preventing acute (but not delayed) emesis associated with cancer chemotherapy. Relatively ineffective versus central emetic stimuli	5-HT ₃ receptors are involved in regulating GI motility so blockade could disrupt these physiological functions 5-HT ₃ receptors involved in sleep-induced apnoea; ondansetron inhibits this phenomenon	Pre-licensing safety studies not performed. Dose escalation studies in for human toxicity suggests safe at 100 times normal dose	213 (2b) 214 (2b) 215 (2b) 216 (1b) 217 (1b) 218 [2b] 114 (1b) 219 [2b] 220 (3b) 221 (1b) 222 (2b)	B
Maropitant: standard emesis 1mg/kg s.c. q24h. For prevention of motion sickness up to 8mg/kg p.o. q24h for maximum of 2 days	NK ₁ receptor antagonists (highly selective)	Work well versus both peripheral and central emetogens. Higher dose required to prevent motion sickness Anti-nausea effect more difficult to measure and assess clinically	Binds to voltage dependent calcium channels at very high concentrations; significant inhibition only seen at concentrations 77 times peak plasma concentrations when dosed at 8mg/kg (bradycardia, decrease in BP)	Use with caution in cardiac disease, hepatic disease, hypoproteinaemia and when administering other highly protein bound drugs.*	128 (1b) 129 (1b) 206 (1b) 119 (1b) 114 (1b) 223 (1b) 224 (2b)	A

*Safety of maropitant in lactating/pregnant bitches and in dogs <16 weeks old is not established. US Food and Drug Administration licence contraindicates use in these groups and where GI obstruction or toxin ingestion suspected. European Medicines Agency (EMA) Summary of Product Characteristics advises risk/benefit assessment by veterinarian in these situations.

CANCER CHEMOTHERAPY AND EMESIS

Nausea and vomiting are among the most feared complications of chemotherapy and the owner of an animal with cancer is often more concerned about the well-being of the patient than about the success of a treatment. Nausea and vomiting in an animal with cancer can be explained by three main mechanisms:

- The localisation of the tumour: gastrointestinal tract (oesophagus, stomach, intestine), liver or pancreas (Sullivan and others 1987 [4b], Wang and others 2002 [4c]).
- Associated paraneoplastic syndromes (e.g. mastocytoma, APUDoma) (O'Keefe and others 1987 [4c], Zerbe and others 1989 [4c]).
- The treatment (surgery, radiotherapy and, most importantly, chemotherapy) (Gyls and others 1979 [2b]).

Here, we will only discuss nausea and vomiting originating from chemotherapy in dogs. Treatment has changed over time because of better understanding of the pathophysiology, more insight in the relationship between the different drugs used in cancer chemotherapy and, finally, the development of new drugs. [OEG C].

Pathophysiology and origin of vomiting

Three types of vomiting due to cancer chemotherapy can be distinguished:

- Anticipated vomiting, which is frequently seen in human medicine but is very rare in our domestic animals. It corresponds to a Pavlov-like type of reflex and is dependent on the memory (e.g. visual stimuli, stimuli by odour related to the clinic, the hospitalisation or personnel). In this type of vomiting it is important to treat with an antiemetic before chemotherapy to avoid activation of the reflex. Whilst there is evidence of nausea and emesis as a conditioned response in humans receiving chemotherapy, there is no published evidence for these mechanisms in dogs.
- Acute vomiting, which can manifest during the first 24 hours after

chemotherapy and can be caused by either central (chemoreceptor trigger zone) or peripheral stimulation. This is the predominant mode of action of cytotoxic drugs.

- Delayed vomiting which starts between 1 and 5 days after treatment (Fukui and Yamamoto 1999 [1b]). Its mechanism is complex and multi-factorial. It may be attributed to a reduction in intestinal motility or to alteration of the intestinal mucosa and its release of hormones (serotonin, norepinephrine) or to a reduction of urinary cortisol excretion. It can also be the result of accumulation of metabolites of cytotoxic agents (especially those derived from platinum).

[OEG C].

Classification of the risks of emesis

The risk of and severity of emesis seen varies according to the cytotoxic agent used and may be classified as heavy, moderate, weak and minimal (Jordan and others 2005 [3a]) (Table 11).

Prevention and treatment of vomiting in the dog

Whilst, in human medicine, there are accepted protocols for the management of chemotherapy induced nausea and vomiting, these have yet to be established in veterinary medicine. Until recently the antiemetics commonly used to treat emesis associated with chemotherapy in canine medicine were metoclopramide and ondansetron. Controlled clinical trials of these drugs are, however, scarce, and no studies have demonstrated their effectiveness in placebo controlled trials in tumour bearing dogs. Other drugs have been investigated; butorphanol was moderately effective in clinical cases of lymphoma receiving cisplatin and ginger extracts have also been tested against cisplatin-induced emesis in dogs, with suggested benefit (Moore and others 1994 [1b], Sharma and others 1997 [2b]). In the 1990s, the discovery of the anti-serotonergics (e.g. ondansetron) led to improved prevention of acute emesis but delayed vomiting was still frequently seen (Sagrada and others

Table 11: Anticipated severity of vomiting according to the cytotoxic drug used. Adapted from 225 [3a]. [OEG C.]

TYPE OF VOMITING	CYTOTOXIC DRUG
Severe	Cisplatin
	Dacarbazine
	Streptozotocin
	Actinomycin
Moderate	Cyclophosphamide
	Doxorubicin
	Methotrexate
	Carboplatin
	Mitoxantrone
	Ilosofamide
Mild	Asparaginase
	Docetaxel
	5 Fluorouracil
	Thiotepa
	Paclitaxel
	Vinblastine
	Vinorelbine
Minimal	Bleomycin
	Busulfan
	Chlorambucil
	Hydroxyurea
	Vincristine
Interferon (α , β , γ)	

1991 [1b]). A small experimental trial of cisplatin-induced emesis in dogs showed that pre-treatment with both ondansetron and granisetron could significantly inhibit vomiting (Topal and others 2005 [3b]). Recently, the NK-1 antagonist, maropitant, has proven its efficacy in the prevention of emesis after treatment with cisplatin in the clinic (De La Puente-Redondo and others 2007b [1b], Vail and others 2007 [1b]). [OEG A].

CONCLUSION

Undertaking this extensive review of the literature relating to the aetiology, diagnosis and management of emesis in dogs has emphasised how much of accepted practice is based on little peer-reviewed evidence, with much extrapolation from human medicine and application of expert experience and opinion. This review highlights those important clinical questions of genuine uncertainty and should provide a basis to direct future clinical studies.



Acknowledgements

The authors would like to acknowledge the help and support of Pfizer Animal Health, the manufacturers of maropitant.

References

ABE, T., KIESER, T. M., TOMITA, T. & EASTON, P. A. (1994) Respiratory muscle function during emesis in awake canines. *Journal of Applied Physiology* **76**, 2552-2560

ABE, T., KUSUHARA, N., KATAGIRI, H., TOMITA, T. & EASTON, P. A. (1993) Differential function of the costal and crural diaphragm during emesis in canines. *Respiratory Physiology* **91**, 183-193

ABOOD, S. K. & BUFFINGTON, C. A. (1992) Enteral feeding of dogs and cats: 51 cases (1989-1991). *Journal of the American Veterinary Medical Association* **201**, 619-622

AROCHE, I., NYSKA, A., GAL, R. & BARK, H. (1997) Functional intestinal hypomotility in association with neuronal damage in a dog. *Journal of Small Animal Practice* **38**, 119-123

BELLENGER, C. R., MADDISON, J. E., MACPHERSON, G. C. & IUKIW, J. E. (1990) Chronic hypertrophic pyloric gastropathy in 14 dogs. *Australian Veterinary Journal* **67**, 317-320

BENCHAOUI, H. A., SIEDEK, E. M., DE LA PUENTE-REDONDO VA, TILT, N., ROWAN, T. G. & CLEMENCE, R. G. (2007) Efficacy of maropitant for preventing vomiting associated with motion sickness in dogs. *Veterinary Record* **161**, 444-447

BHARGAVA, K. P., DIXIT, K. S. & PALIT, G. (1976) Nature of histamine receptors in the emetic chemoreceptor trigger zone. *British Journal of Pharmacology* **57**, 211-213

BOAG, A. K., COE, R. J., MARTINEZ, T. A. & HUGHES, D. (2005) Acid-base and electrolyte abnormalities in dogs with gastrointestinal foreign bodies. *Journal of Veterinary Internal Medicine* **19**, 816-821

BORISON, H. L. (1985) A misconception of motion sickness leads to false therapeutic expectations. *Aviation, space and environmental medicine* **56**, 66-68

BOYD, W. J. (1953) Carsickness in dogs. *Journal of the American Veterinary Medical Association* **122**, 198-199

BRIGGS, D. B. & CARPENTER, D. O. (1986) Excitation of neurons in the canine area postrema by prostaglandins. *Cellular and molecular neurobiology* **6**, 421-426

CAPAK, D., SIMPRAGA, M., MATIC, D., BALI, R. & JANOSKA, B. (2001) Incidence of foreign-body-induced ileus in dogs. *Berliner und Münchener tierärztliche Wochenschrift* **114**, 290-296

CARPENTER, D. O. & BRIGGS, D. B. (1986) Insulin excites neurons of the area postrema and causes emesis. *Neuroscience Letters* **68**, 85-89

CARPENTER, D. O., BRIGGS, D. B., KNOX, A. P. & STROMINGER, N. (1988) Excitation of area postrema neurons by transmitters, peptides, and cyclic nucleotides. *Journal of Neurophysiology* **59**, 358-369

CARPENTER, D. O., BRIGGS, D. B. & STROMINGER, N. (1983) Responses of neurons of canine area postrema to neurotransmitters and peptides. *Cellular and molecular neurobiology* **3**, 113-126

CHANDLER, M. L. & PAYNE-JAMES, J. J. (2006) Prospective evaluation of a peripherally administered three-in-one parenteral nutrition product in dogs. *Journal of Small Animal Practice* **47**, 518-523

CHERNICKY, C. L., BARNES, K. L., CONOMY, J. P. & FERRARIO, C. M. (1980) A morphological characterization of the canine area postrema. *Neuroscience Letters* **20**, 37-43

CONDER G. A., SEDLACEK, H. S., BOUCHER, J. F. & CLEMENCE R. G. (2008) Efficacy and safety of maropitant, a selective neurokinin 1 receptor antagonist, in two randomized clinical trials for prevention of vomiting due to motion sickness in dogs. *Journal of Veterinary Pharmacology and Therapeutics* **31**, 528-532.

CORNELIUS, L. M. & RAWLINGS, C. A. (1981) Arterial blood gas and acid-base values in dogs with various diseases and signs of disease. *Journal of the American Veterinary Medical Association* **178**, 992-995

DE LA PUENTE-REDONDO, V. A., SIEDEK, E. M., BENCHAOUI, H. A., TILT, N., ROWAN, T. G. & CLEMENCE, R. G. (2007a) The anti-emetic efficacy of maropitant (Cerenia) in the treatment of ongoing emesis caused by a wide range of underlying clinical aetiologies in canine patients in Europe. *Journal of Small Animal Practice* **48**, 93-98

DE LA PUENTE-REDONDO, V. A., TILT, N., ROWAN, T. G. & CLEMENCE, R. G. (2007b) Efficacy of maropitant for treatment and prevention of emesis caused by intravenous infusion of cisplatin in dogs. *American Journal of Veterinary Research* **68**, 48-56

DEVAUCHELLE, P., ELLIOT, J., ELWOOD, C., FREICHE, V., GERMAN, A., GUALTIERI, M., HALL, E., DEN HERTOG, E., NEIGER, R., PEETERS, D. & ROURA, X. (2006) Approach to the management of emesis in dogs. Current guidelines to best practice from the European Emesis Council. Pfizer, Animal Health, Sandwich, Kent, UK.

FUKUDA, H. & KOGA, T. (1991) The Botzinger complex as the pattern generator for retching and vomiting in the dog. *Neuroscience Research* **12**, 471-485

FUKUDA, H. & KOGA, T. (1992) Non-respiratory neurons in the Botzinger complex exhibiting appropriate firing patterns to generate the emetic act in dogs. *Neuroscience Research* **14**, 180-194

FUKUI, H. & YAMAMOTO, M. (1999) Methotrexate produces delayed emesis in dogs: a potential model of delayed emesis induced by chemotherapy. *European Journal of Pharmacology* **372**, 261-267

FUKUI, H., YAMAMOTO, M., ANDO, T., SASAKI, S. & SATO, S. (1993a) Increase in serotonin levels in the dog ileum and blood by cisplatin as measured by microdialysis. *Neuropharmacology* **32**, 959-968

FUKUI, H., YAMAMOTO, M., SASAKI, S. & SATO, S. (1993b) Emetic effects of anticancer drugs and involvement of visceral afferent fibers and 5-HT₃ receptors in dogs. *European Journal of Pharmacology* **250**, 281-287

FUKUI, H., YAMAMOTO, M. & SATO, S. (1992) Vagal afferent fibers and peripheral 5-HT₃ receptors mediate cisplatin-induced emesis in dogs. *Japanese journal of pharmacology* **59**, 221-226

FURUKAWA, N. & OKADA, H. (1994) Canine salivary secretion from the submaxillary glands before and during retching. *American Journal of Physiology* **267**, G810-G817

GUALTIERI M. (1996) Gastrointestinal polyps in small animals. *European Journal of Comparative Gastroenterology* **1**, 1-11

GUALTIERI, M., MONZEGGIO, M. G. & SCANZIANI, E. (1999) Gastric neoplasia. *The Veterinary Clinics of North America. Small animal practice* **29**, 415-440

GYLIS, J. A., DORAN, K. M. & BUYNISKI, J. P. (1979) Antagonism of cisplatin induced emesis in the dog. *Research Communications in Chemical Pathology and Pharmacology* **23**, 61-68

HIKASA, Y., TAKASE, K., OSADA, T., TAKAMATSU, H. & OGASAWARA, S. (1987) Xylazine-induced vomiting in dogs: elimination by ablation of the area postrema and blockade by yohimbine. *Zentralblatt für Veterinärmedizin. Reihe A* **34**, 154-158

HUBBARD, K., SKELLY, B. J., MCKELVIE, J. & WOOD, J. L. (2007) Risk of vomiting and diarrhoea in dogs. *Veterinary Record* **161**, 755-757

LESLIE, R. A., NELSON, R. W., FAMULA, T. R. & BANNASCH, L. (2007) Clinical features and heritability of hypoadrenocorticism in Nova Scotia Duck Tolling Retrievers: 25 cases (1994-2006). *Journal of the American Veterinary Medical Association* **231**, 407-412

JOHNSON, C. S., FALES-WILLIAMS, A. J., REIMER, S. B., LOTSIKAS, P. J. & HAYNES, J. S. (2007) Fibrosing gastrointestinal leiomyositis as a cause of chronic intestinal pseudo-obstruction in an 8-month-old dog. *Veterinary Quarterly* **44**, 106-109

JORDAN, K., KASPER, C. & SCHMOLL, H. J. (2005) Chemotherapy-induced nausea and vomiting: current

and new standards in the antiemetic prophylaxis and treatment. *European Journal of Cancer* **41**, 199-205

KINTZER, P. P. & PETERSON, M. E. (1997) Primary and secondary canine hypoadrenocorticism. *The Veterinary Clinics of North America. Small animal practice* **27**, 349-357

KOGA, T. & FUKUDA, H. (1990) Characteristic behavior of the respiratory muscles, esophagus, and external anal and urethral sphincters during straining, retching, and vomiting in the decerebrate dog. *Japanese Journal of Physiology* **40**, 789-807

KOGA, T. & FUKUDA, H. (1992) Neurons in the nucleus of the solitary tract mediating inputs from emetic vagal afferents and the area postrema to the pattern generator for the emetic act in dogs. *Neuroscience Research* **14**, 166-179

KOGA, T. & FUKUDA, H. (1997) Descending pathway from the central pattern generator of vomiting. *Neuroreport* **8**, 2587-2590

KOGA, T., QU, R. & FUKUDA, H. (1998) The central pattern generator for vomiting may exist in the reticular area dorsomedial to the retrofacial nucleus in dogs. *Experimental brain research* **118**, 139-147

KOGAN, D. A., JOHNSON, L. R., STURGES, B. K., JANDREY, K. E. & POLLARD, R. E. (2008) Etiology and clinical outcome in dogs with aspiration pneumonia: 88 cases (2004-2006). *Journal of the American Veterinary Medical Association* **233**, 1748-1755

KORDA, P. (1972) Epimeletic vomiting in female dogs during the rearing process of their puppies. *Acta neurobiologiae experimentalis* **32**, 733-747

KORETZ, R. L., AVENELL, A., LIPMAN, T. O. (2007) Does Enteral Nutrition Affect Clinical Outcome? A Systematic Review of the Randomized Trials. *American Journal of Clinical Nutrition* **102**: 412-429

LANG, I. M., DANA, N., MEDDA, B. K. & SHAKER, R. (2002) Mechanisms of airway protection during retching, vomiting, and swallowing. *American journal of physiology. Gastrointestinal and liver physiology* **283**, G529-G536

LANG, I. M. & MARVIG, J. (1989) Functional localization of specific receptors mediating gastrointestinal motor correlates of vomiting. *American Journal of Physiology* **256**, G92-G99

LANG, I. M., MARVIG, J. & SARNA, S. K. (1988) Comparison of gastrointestinal responses to CCK-8 and associated with vomiting. *American Journal of Physiology* **254**, G254-G263

LANG, I. M., MARVIG, J., SARNA, S. K. & CONDON, R. E. (1986a) Gastrointestinal myoelectric correlates of vomiting in the dog. *American Journal of Physiology* **251**, G830-G838

LANG, I. M., SARNA, S. K. & CONDON, R. E. (1986b) Gastrointestinal motor correlates of vomiting in the dog: quantification and characterization as an independent phenomenon. *Gastroenterology* **90**, 40-47

LANG, I. M., SARNA, S. K. & DODDS, W. J. (1993) Pharyngeal, esophageal, and proximal gastric responses associated with vomiting. *American Journal of Physiology* **265**, G963-G972

LESLIE, R. A., McDONALD, T. J. & ROBERTSON, H. A. (1988) Autoradiographic localization of peptide YY and neuropeptide Y binding sites in the medulla oblongata. *Peptides* **9**, 1071-1076

LIPPERT, A. C., FULTON, R. B., JR. & PARR, A. M. (1993) A retrospective study of the use of total parenteral nutrition in dogs and cats. *Journal of Veterinary Internal Medicine* **7**, 52-64

MICHEL, K. E. & HIGGINS, C. (2006) Investigation of the percentage of prescribed enteral nutrition actually delivered to hospitalized companion animals. *Journal of Veterinary Emergency and Critical Care* **16**, S2-S6

MOHR, A. J., LEISEWITZ, A. L., JACOBSON, L. S., STEINER, J. M., RUAUX, C. G. & WILLIAMS, D. A. (2003) Effect of early enteral nutrition on intestinal permeability, intestinal protein loss, and outcome in dogs with severe parvoviral enteritis. *Journal of Veterinary Internal Medicine* **17**, 791-798

MOORE, A. S., RAND, W. M., BERG, J., L'HEUREUX, D. A. & DENNIS, R. A. (1994) Evaluation of butorphanol and



cyproheptadine for prevention of cisplatin-induced vomiting in dogs. *Journal of the American Veterinary Medical Association* **205**, 441-443

O'KEEFE, D. A., COUTO, C. G., BURKE-SCHWARTZ, C. & JACOBS, R. M. (1987) Systemic mastocytosis in 16 dogs. *Journal of Veterinary Internal Medicine* **1**, 75-80

ONISHI, T., MORI, T., YANAGIHARA, M., FURUKAWA, N. & FUKUDA, H. (2007) Similarities of the neuronal circuit for the induction of fictive vomiting between ferrets and dogs. *Autonomic neuroscience* **136**, 20-30

QIN, H. L., SU, Z. D., HU, L. G., DING, Z. X. & LIN, Q. T. (2002) Effect of early intrajejunal nutrition on pancreatic pathological features and gut barrier function in dogs with acute pancreatitis. *Clinical Nutrition* **21**, 469-473

SAGRADA, A., TURCONI, M., BONALI, P., SCHIANTARELLI, P., MICHELETTI, R., MONTAGNA, E., NICOLA, M., ALGATE, D. R., RIMOLDI, E. M. & DONETTI, A. (1991) Antiemetic activity of the new 5-HT₃ antagonist DAU 6215 in animal models of cancer chemotherapy and radiation. *Cancer chemotherapy and pharmacology* **28**, 470-474

SANDHU, B. K. (2001) Rationale for early feeding in childhood gastroenteritis. *Journal of Pediatric Gastroenterology and Nutrition* **33** Suppl 2, S13-S16

SANGER, G. J. & ANDREWS, P. L. (2006) Treatment of nausea and vomiting: gaps in our knowledge. *Autonomic neuroscience* **129**, 3-16

SAUTTER, J. H. & HANLON, G. F. (1975) Gastric neoplasms in the dog: a report of 20 cases. *Journal of the American Veterinary Medical Association* **166**, 691-696

SCANZIANI, E., GIUSTI, A., GUALTIERI, M. & FONDA, D. (1991) Gastric carcinoma in the Belgian shepherd dog. *Journal of Small Animal Practice* **32**, 465-469

SHA, S., MATSUSHIMA, Y., HABU, S., MISHIMA, Y. & OKAMOTO, E. (1996) Extrinsic nervous control of retrograde giant contraction during vomiting in conscious dogs. *Digestive Diseases and Sciences* **41**, 1546-1550

SHARMA, S. S., KOCHUPILLAI, V., GUPTA, S. K., SETH, S. D. & GUPTA, Y. K. (1997) Antiemetic efficacy of ginger (*Zingiber officinale*) against cisplatin-induced emesis in dogs. *Journal of Ethnopharmacology* **57**, 93-96

STAFANINI, E. & CLEMENT-CORMIER, Y. (1981) Detection of dopamine receptors in the area postrema. *European Journal of Pharmacology* **74**, 257-260

SULLIVAN, M., LEE, R., FISHER, E. W., NASH, A. S. & McCANDLISH, I. A. (1987) A study of 31 cases of gastric carcinoma in dogs. *Veterinary Record* **120**, 79-83

TOPAL, A., KAYA, M. & GUL, N. (2005) Ondansetron and granisetron in the prophylaxis of nausea induced by cisplatin in dogs. *Acta Veterinaria Brno* **74**, 111-116

VAIL, D. M., RODABAUGH, H. S. & CONDER, G. A. (2007) Efficacy of injectable maropitant (CereniaTM) in a randomized clinical trial for prevention and treatment of cisplatin-induced emesis in dogs presented as veterinary patients. *Veterinary and comparative oncology* **5**, 38-46

VALVERDE, A., CANTWELL, S., HERNANDEZ, J. & BROTHERSON, C. (2004) Effects of acepromazine on the incidence of vomiting associated with opioid administration in dogs. *Veterinary Anaesthesia and Analgesia* **31**, 40-45

WALTER, M. C., GOLDSCHMIDT, M. H., STONE, E. A., DOUGHERTY, J. F. & MATTHIESEN, D. T. (1985) Chronic hypertrophic pyloric gastropathy as a cause of pyloric obstruction in the dog. *Journal of the American Veterinary Medical Association* **186**, 157-161

WANG, F. I., LEE, J. J., LIU, C. H., PANG, V. F., CHANG, P. H. & JENG, C. R. (2002) Scirrhous gastric carcinoma with mediastinal invasion in a dog. *Journal of veterinary diagnostic investigation* **14**, 65-68

WANG, S. C. & CHINN, H. I. (1954) Experimental motion sickness in dogs; functional importance of chemoreceptive emetic trigger zone. *American Journal of Physiology* **178**, 111-116

WILL, K., NOLTE, I. & ZENTEK, J. (2005) Early enteral nutrition in young dogs suffering from haemorrhagic

gastroenteritis. *Journal of veterinary medicine. A, Physiology, pathology, clinical medicine* **52**, 371-376

XU, G. F., LU, Z., GAO, J., LI, Z. S. & GONG, Y. F. (2006) Effect of ecomimmunonutrition supports on maintenance of integrity of intestinal mucosal barrier in severe acute pancreatitis in dogs. *Chinese Medical Journal (English)* **119**, 656-661

XU, J. & CHEN, J. D. (2008) Intestinal electrical stimulation improves delayed gastric emptying and vomiting induced by duodenal distension in dogs. *Neurogastroenterology and motility* **20**, 236-242

XU, G. P. (2006) Parenteral nutrition in adult inpatients with functioning gastrointestinal tracts: assessment of outcomes. *Lancet* **367**, 1101-1111

ZERBE, C. A., BOOSINGER, T. R., GRABAU, J. H., PLETCHER, J. M. & O'DORISIO, T. M. (1989) Pancreatic polypeptide and insulin-secreting tumour in a dog with duodenal ulcers and hypertrophic gastritis. *Journal of Veterinary Internal Medicine* **3**, 178-182

APPENDIX 1

References to tables

1. OXFORD CENTRE FOR EVIDENCE BASED MEDICINE (2001) <http://www.cebm.net/index.aspx?o=1047> Accessed March 17th 2009.
2. HAYDEN, D. W. & FLEISCHMAN, R. W. (1977) Scirrhous eosinophilic gastritis in dogs with gastric arteritis. *Veterinary Quarterly* **14**, 441-448
3. ROUSSEAU, M. (2005) Severe lymphocytic-plasmacytic and atrophic gastritis, as well as, predominantly eosinophilic, severe enteritis, in a 19-month-old Labrador retriever. *Canadian Veterinary Journal* **46**, 264-267
4. TYSZKO, C., BRIGHT, J. M. & SWIST, S. L. (2007) Recurrent supraventricular arrhythmias in a dog with atrial myocarditis and gastritis. *Journal of Small Animal Practice* **48**, 335-338
5. VAN DER GAAG, I., HAPPE, R. P. & WOLVEKAMP, W. T. (1976) A boxer dog with chronic hypertrophic gastritis resembling Menetrier's disease in man. *Veterinary Quarterly* **13**, 172-185
6. VAN DER GAAG, I. & HAPPE, R. P. (1989) Follow-up studies by peroral gastric biopsies and necropsy in vomiting dogs. *Canadian Journal of Veterinary Research* **53**, 468-472
7. HAPPONEN, I., LINDEN, J., SAARI, S., KARJALAINEN, M., HANNINEN, M. L., JALAVA, K. & WESTERMARCK, E. (1998) Detection and effects of helicobacters in healthy dogs and dogs with signs of gastritis. *Journal of the American Veterinary Medical Association* **213**, 1767-1774
8. LEIB, M. S., DUNCAN, R. B. & WARD, D. L. (2007) Triple antimicrobial therapy and acid suppression in dogs with chronic vomiting and gastric Helicobacter spp. *Journal of Veterinary Internal Medicine* **21**, 1185-1192
9. WIINBERG, B., SPOHR, A., DIETZ, H. H., EGELUND, T., GREITER-WILKE, A., McDONOUGH, S. P., OLSEN, J., PRIESTNALL, S., CHANG, Y. F. & SIMPSON, K. W. (2005) Quantitative analysis of inflammatory and immune responses in dogs with gastritis and their relationship to Helicobacter spp. infection. *Journal of Veterinary Internal Medicine* **19**, 4-14
10. SULLIVAN, M., LEE, R., FISHER, E. W., NASH, A. S. & McCANDLISH, I. A. (1987) A study of 31 cases of gastric carcinoma in dogs. *Veterinary Record* **120**, 79-83
11. SAUTTER, J. H. & HANLON, G. F. (1975) Gastric neoplasms in the dog: a report of 20 cases. *Journal of the American Veterinary Medical Association* **166**, 691-696
12. GILMOUR, M. A. & WALSHAW, R. (1987) Naproxen-induced toxicosis in a dog. *Journal of the American Veterinary Medical Association* **191**, 1431-1432
13. SENNELLO, K. A. & LEIB, M. S. (2006) Effects of deracoxib or buffered aspirin on the gastric mucosa of healthy dogs. *Journal of Veterinary Internal Medicine* **20**, 1291-1296

14. VONDERHAAR, M. A. & SALISBURY, S. K. (1993) Gastrointestinal ulceration associated with flunixin meglumine administration in three dogs. *Journal of the American Veterinary Medical Association* **203**, 92-95
15. STEINBERG, H., DUBIELZIG, R. R., THOMSON, J. & DZATA, G. (1995) Primary gastrointestinal lymphosarcoma with epitheliotropism in three Shar-pei and one boxer dog. *Veterinary Quarterly* **32**, 423-426
16. KINTZER, P. P. & PETERSON, M. E. (1991) Mitotane (o,p'-DDD) treatment of 200 dogs with pituitary-dependent hyperadrenocorticism. *Journal of Veterinary Internal Medicine* **5**, 182-190
17. HAPPE, R. P., VAN, D. G., I, LAMERS, C. B., VAN TOORENBURG, J., REHFELD, J. F. & LARSSON, L. I. (1980) Zollinger-Ellison syndrome in three dogs. *Veterinary Quarterly* **17**, 177-186
18. SHAW, D. H. (1988) Gastrinoma (Zollinger-Ellison Syndrome) in the Dog and cat. *Canadian Veterinary Journal* **29**, 448-452
19. LIFTON, S. J., KING, L. G. & ZERBE, C. A. (1996) Glucocorticoid deficient hypoadrenocorticism in dogs: 18 cases (1986-1995). *Journal of the American Veterinary Medical Association* **209**, 2076-2081
20. O'KEEFE, D. A., COUTO, C. G., BURKE-SCHWARTZ, C. & JACOBS, R. M. (1987) Systemic mastocytosis in 16 dogs. *Journal of Veterinary Internal Medicine* **1**, 75-80
21. MINIHAN, A. C., BERG, J. & EVANS, K. L. (2004) Chronic diaphragmatic hernia in 34 dogs and 16 cats. *Journal of the American Animal Hospitals Association* **40**, 51-63
22. CALLAN, M. B., WASHABAU, R. J., SAUNDERS, H. M., KERR, L., PRYMAK, C. & HOLT, D. (1993) Congenital esophageal hiatal hernia in the Chinese shar-pei dog. *Journal of Veterinary Internal Medicine* **7**, 210-215
23. MILES, K. G., POPE, E. R. & JERGENS, A. E. (1988) Paraesophageal hiatal hernia and pyloric obstruction in a dog. *Journal of the American Veterinary Medical Association* **193**, 1437-1439
24. PEARSON, H. (1979) Pyloric stenosis in the dog. *Veterinary Record* **105**, 393-394
25. PEETERS, M. E. (1991) [Pyloric stenosis in the dog: developments in its surgical treatment and retrospective study in 47 patients]. *Tijdschrift voor diergeneeskunde* **116**, 137-141
26. WALSH, M. H. & QUIGLEY, P. J. (1966) Pyloric stenosis in the dog caused by hypertrophy of the circular muscle of the pylorus. *Veterinary Record* **78**, 13-15
27. BELLENGER, C. R., MADDISON, J. E., MACPHERSON, G. C. & ILKIW, J. E. (1990) Chronic hypertrophic pyloric gastropathy in 14 dogs. *Australian Veterinary Journal* **67**, 317-320
28. LEIB, M. S., SAUNDERS, G. K., MOON, M. L., MANN, M. A., MARTIN, R. A., MATZ, M. E., NIX, B., SMITH, M. M. & WALDRON, D. R. (1993) Endoscopic diagnosis of chronic hypertrophic pyloric gastropathy in dogs. *Journal of Veterinary Internal Medicine* **7**, 335-341
29. DEN HERTOEG, E. (2003) [Endoscopic removal of foreign bodies from cats or dogs]. *Tijdschrift voor diergeneeskunde* **128**, 434-439
30. HORSTMAN, C. L., EUBIG, P. A., CORNELL, K. K., KHAN, S. A. & SELCER, B. A. (2003) Gastric outflow obstruction after ingestion of wood glue in a dog. *Journal of the American Animal Hospitals Association* **39**, 47-51
31. TYRRELL, D. & BECK, C. (2006) Survey of the use of radiography vs. ultrasonography in the investigation of gastrointestinal foreign bodies in small animals. *Veterinary Radiology and Ultrasound* **47**, 404-408
32. WHITE, S. D. (1986) Food hypersensitivity in 30 dogs. *Journal of the American Veterinary Medical Association* **188**, 695-698
33. SCHREINER, N. M., GASCHEN, F., GRONE, A., SAUTER, S. N. & ALLENSPACH, K. (2008) Clinical signs, histology, and CD3-positive cells before and after treatment of dogs with chronic enteropathies.



- Journal of Veterinary Internal Medicine* **22**, 1079-1083
34. MACARTNEY, L., McCANDLISH, I. A., THOMPSON, H. & CORNWELL, H. J. (1984) Canine parvovirus enteritis 1: Clinical, haematological and pathological features of experimental infection. *Veterinary Record* **115**, 201-210
 35. MEUNIER, P. C., COOPER, B. J., APPEL, M. J. & SLAUSON, D. O. (1985) Pathogenesis of canine parvovirus enteritis: the importance of viremia. *Veterinary Quarterly* **22**, 60-71
 36. EVERMANN, J. F., ABBOTT, J. R. & HAN, S. (2005) Canine coronavirus-associated puppy mortality without evidence of concurrent canine parvovirus infection. *Journal of veterinary diagnostic investigation* **17**, 610-614
 37. MORSE, E. V. & DUNCAN, M. A. (1975) Canine salmonellosis: prevalence, epizootiology, signs, and public health significance. *Journal of the American Veterinary Medical Association* **167**, 817-820
 38. OLSON, P. & SANDSTEDT, K. (1987) *Campylobacter* in the dog: a clinical and experimental study. *Veterinary Record* **121**, 99-101
 39. TURINELLI, V., LEDIEU, D., GUILBAUD, L., MARCHAL, T., MAGNOL, J. P. & FOURNEL-FLEURY, C. (2004) Mycobacterium tuberculosis infection in a dog from Africa. *Veterinary Clinical Pathology* **33**, 177-181
 40. MALIK, R., DILL-MACKY, E., MARTIN, P., WIGNEY, D. I., MUIR, D. B. & LOVE, D. N. (1995) Cryptococcosis in dogs: a retrospective study of 20 consecutive cases. *Journal of medical and veterinary mycology* **33**, 291-297
 41. MALIK, R., HUNT, G. B., BELLENGER, C. R., ALLAN, G. S., MARTIN, P., CANFIELD, P. J. & LOVE, D. N. (1999) Intra-abdominal cryptococcosis in two dogs. *Journal of Small Animal Practice* **40**, 387-391
 42. MILLER, R. I. (1985) Gastrointestinal phycosporidiosis in 63 dogs. *Journal of the American Veterinary Medical Association* **186**, 473-478
 43. THEISEN, S. K., LEGRANGE, S. N., JOHNSON, S. E., SHERDING, R. G. & WILLARD, M. D. (1998) Physaloptera infection in 18 dogs with intermittent vomiting. *Journal of the American Animal Hospitals Association* **34**, 74-78
 44. JERGENS, A. E., MOORE, F. M., HAYNES, J. S. & MILES, K. G. (1992) Idiopathic inflammatory bowel disease in dogs and cats: 84 cases (1987-1990). *Journal of the American Veterinary Medical Association* **201**, 1603-1608
 45. COUTO, C. G., RUTGERS, H. C., SHERDING, R. G. & ROJKO, J. (1989) Gastrointestinal lymphoma in 20 dogs. A retrospective study. *Journal of Veterinary Internal Medicine* **3**, 73-78
 46. JUOPPERI, T. A., CESTA, M., TOMLINSON, L. & GRINDEM, C. B. (2003) Extensive cutaneous metastases in a dog with duodenal adenocarcinoma. *Veterinary Clinical Pathology* **32**, 88-91
 47. PAOLONI, M. C., PENNINCK, D. G. & MOORE, A. S. (2002) Ultrasonographic and clinicopathologic findings in 21 dogs with intestinal adenocarcinoma. *Veterinary Radiology and Ultrasound* **43**, 562-567
 48. SAKO, T., UCHIDA, E., OKAMOTO, M., YAMAMOTO, E., KAGAWA, Y., YOSHINO, T., HIRAYAMA, K. & TANIYAMA, H. (2003) Immunohistochemical evaluation of a malignant intestinal carcinoid in a dog. *Veterinary Quarterly* **40**, 212-215
 49. WILSON, G. P. & BURT, J. K. (1974) Intussusception in the dog and cat: a review of 45 cases. *Journal of the American Veterinary Medical Association* **164**, 515-518
 50. BENTLEY, A. M., O'TOOLE, T. E., KOWALESKI, M. P., CASALE, S. A. & MCCARTHY, R. J. (2005) Volvulus of the colon in four dogs. *Journal of the American Veterinary Medical Association* **227**, 253-257
 51. SHEALY, P. M. & HENDERSON, R. A. (1992) Canine intestinal volvulus. A report of nine new cases. *Veterinary Surgery* **21**, 15-19
 52. HASSINGER, K. A. (1997) Intestinal entrapment and strangulation caused by rupture of the duodenocolic ligament in four dogs. *Veterinary Surgery* **26**, 275-280
 53. HARKIN, K. R., ANDREWS, G. A. & NIETFIELD, J. C. (2002) Dysautonomia in dogs: 65 cases (1993-2000). *Journal of the American Veterinary Medical Association* **220**, 633-639
 54. NIESSEN, S. J., EASTWOOD, J., SMYTH, J. B. & CHERUBINI, G. B. (2007) Five cases of canine dysautonomia in England (2004 to 2006). *Journal of Small Animal Practice* **48**, 346-352
 55. AROCH, I., NYSKA, A., GAL, R. & BARK, H. (1997) Functional intestinal hypomotility in association with neuronal damage in a dog. *Journal of Small Animal Practice* **38**, 119-123
 56. ARRIK, R. H. & KLEINE, L. J. (1978) Intestinal pseudoobstruction in a dog. *Journal of the American Veterinary Medical Association* **172**, 1201-1205
 57. DVIR, E., LEISEWITZ, A. L. & VAN DER LUGT, J. J. (2001) Chronic idiopathic intestinal pseudo-obstruction in an English bulldog. *Journal of Small Animal Practice* **42**, 243-247
 58. EASTWOOD, J. M., McINNES, E. F., WHITE, R. N., ELWOOD, C. M. & STOCK, G. (2005) Caecal impaction and chronic intestinal pseudo-obstruction in a dog. *Journal of veterinary medicine. A, Physiology, pathology, clinical medicine* **52**, 43-44
 59. KIM, J. H., CHOI, Y. K., YOON, H. Y., KWON, O. K. & KIM, D. Y. (2002) Juvenile malignant mesothelioma in a dog. *Journal of Veterinary Medicine and Science* **64**, 269-271
 60. KOMORI, S., NAKAGAKI, K., KOYAMA, H. & YAMAGAMI, T. (2002) Idiopathic mesenteric and omental steatitis in a dog. *Journal of the American Veterinary Medical Association* **221**, 1591-3, 1574
 61. BELLAH, J. R. (1983) Colonic perforation after corticosteroid and surgical treatment of intervertebral disk disease in a dog. *Journal of the American Veterinary Medical Association* **183**, 1002-3, 965
 62. MOORE, M. P. & ROBINETTE, J. D. (1987) Cecal perforation and adrenocortical adenoma in a dog. *Journal of the American Veterinary Medical Association* **191**, 87-88
 63. KIRPENSTEIJN, J., FINGLAND, R. B., ULRICH, T., SIKKEMA, D. A. & ALLEN, S. W. (1993) Cholelithiasis in dogs: 29 cases (1980-1990). *Journal of the American Veterinary Medical Association* **202**, 1137-1142
 64. LUDWIG, L. L., McLOUGHLIN, M. A., GRAVES, T. K. & CRISP, M. S. (1997) Surgical treatment of bile peritonitis in 24 dogs and 2 cats: a retrospective study (1987-1994). *Veterinary Surgery* **26**, 90-98
 65. BOOTHE, H. W., LAY, J. C. & MORELAND, K. J. (1991) Sclerosing encapsulating peritonitis in three dogs. *Journal of the American Veterinary Medical Association* **198**, 267-270
 66. EVES, N. G. (2004) Hepatocellular adenoma in a 12-year-old crossbred German shepherd dog. *Canadian Veterinary Journal* **45**, 326-328
 67. SEVELIUS, E. (1995) Diagnosis and prognosis of chronic hepatitis and cirrhosis in dogs. *Journal of Small Animal Practice* **36**, 521-528
 68. HOFFMANN, G., VAN DEN INGH, T. S., BODE, P. & ROTHUIZEN, J. (2006) Copper-associated chronic hepatitis in Labrador Retrievers. *Journal of Veterinary Internal Medicine* **20**, 856-861
 69. SHIH, J. L., KEATING, J. H., FREEMAN, L. M. & WEBSTER, C. R. (2007) Chronic hepatitis in Labrador Retrievers: clinical presentation and prognostic factors. *Journal of Veterinary Internal Medicine* **21**, 33-39
 70. FOX, J. G., DROLET, R., HIGGINS, R., MESSIER, S., YAN, L., COLEMAN, B. E., PASTER, B. J. & DEWHIRST, F. E. (1996) Helicobacter canis isolated from a dog liver with multifocal necrotizing hepatitis. *Journal of Clinical Microbiology* **34**, 2479-2482
 71. GOLDSTEIN, R. E., LIN, R. C., LANGSTON, C. E., SCRIVANI, P. V., ERB, H. N. & BARR, S. C. (2006) Influence of infecting serogroup on clinical features of leptospirosis in dogs. *Journal of Veterinary Internal Medicine* **20**, 489-494
 72. MILLER, R. I., ROSS, S. P., SULLIVAN, N. D. & PERKINS, N. R. (2007) Clinical and epidemiological features of canine leptospirosis in North Queensland. *Australian Veterinary Journal* **85**, 13-19
 73. ANDERSON, W. I., CAMPBELL, K. L., WILSON, R. C. & GOETSCH, D. D. (1984) Hepatitis in a dog given sulfadiazine-trimethoprim and cyclophosphamide. *Modern Veterinary Practice* **65**, 115
 74. DUNAYER, E. K. & GWALTNEY-BRANT, S. M. (2006) Acute hepatic failure and coagulopathy associated with xylitol ingestion in eight dogs. *Journal of the American Veterinary Medical Association* **229**, 1113-1117
 75. MacPHAIL, C. M., LAPPIN, M. R., MEYER, D. J., SMITH, S. G., WEBSTER, C. R. & ARMSTRONG, P. J. (1998) Hepatocellular toxicosis associated with administration of carprofen in 21 dogs. *Journal of the American Veterinary Medical Association* **212**, 1895-1901
 76. FORRESTER, S. D., ROGERS, K. S. & RELFORD, R. L. (1992) Cholangiohepatitis in a dog. *Journal of the American Veterinary Medical Association* **200**, 1704-1706
 77. O'NEILL, E. J., DAY, M. J., HALL, E. J., HOLDEN, D. J., MURPHY, K. F., BARR, F. J. & PEARSON, G. R. (2006) Bacterial cholangitis/cholangiohepatitis without concurrent cholecystitis in four dogs. *Journal of Small Animal Practice* **47**, 325-335
 78. CORFIELD, G. S., READ, R. A., NICHOLLS, P. K. & LESTER, N. (2007) Gall bladder torsion and rupture in a dog. *Australian Veterinary Journal* **85**, 226-231
 79. SCHWARTZ, S. G., MITCHELL, S. L., KEATING, J. H. & CHAN, D. L. (2006) Liver lobe torsion in dogs: 13 cases (1995-2004). *Journal of the American Veterinary Medical Association* **228**, 242-247
 80. FARRAR, E. T., WASHBAU, R. J. & SAUNDERS, H. M. (1996) Hepatic abscesses in dogs: 14 cases (1982-1994). *Journal of the American Veterinary Medical Association* **208**, 243-247
 81. NEATH, P. J., BROCKMAN, D. J. & SAUNDERS, H. M. (1997) Retrospective analysis of 19 cases of isolated torsion of the splenic pedicle in dogs. *Journal of Small Animal Practice* **38**, 387-392
 82. GINEL, P. J., LUCENA, R., AROLA, J., MARTIN, M. P. & MOZOS, E. (2001) Diffuse splenomegaly caused by splenic abscessation in a dog. *Veterinary Record* **149**, 327-329
 83. HARDIE, E. M., VADEN, S. L., SPAULDING, K. & MALARKEY, D. E. (1995) Splenic infarction in 16 dogs: a retrospective study. *Journal of Veterinary Internal Medicine* **9**, 141-148
 84. TURNQUIST, S. E., COHN, L. A. & REED, A. (1997) Splenic hemangiosarcoma and concurrent ossifying gastric adenocarcinoma in a dog. *Journal of the American Animal Hospitals Association* **33**, 434-437
 85. HESS, R. S., SAUNDERS, H. M., VAN WINKLE, T. J., SHOFER, F. S. & WASHBAU, R. J. (1998) Clinical, clinicopathologic, radiographic, and ultrasonographic abnormalities in dogs with fatal acute pancreatitis: 70 cases (1986-1995). *Journal of the American Veterinary Medical Association* **213**, 665-670
 86. BENNETT, P. F., HAHN, K. A., TOAL, R. L. & LEGENDRE, A. M. (2001) Ultrasonographic and cytopathological diagnosis of exocrine pancreatic carcinoma in the dog and cat. *Journal of the American Animal Hospitals Association* **37**, 466-473
 87. JAEGER, J. Q., MATTOON, J. S., BATEMAN, S. W. & MORANDI, F. (2003) Combined use of ultrasonography and contrast enhanced computed tomography to evaluate acute necrotizing pancreatitis in two dogs. *Veterinary Radiology and Ultrasound* **44**, 72-79
 88. SMITH, S. A. & BILLER, D. S. (1998) Resolution of a pancreatic pseudocyst in a dog following percutaneous ultrasonographic-guided drainage. *Journal of the American Animal Hospitals Association* **34**, 515-522
 89. SALISBURY, S. K., LANTZ, G. C., NELSON, R. W. & KAZACOS, E. A. (1988) Pancreatic abscess in dogs: six cases (1978-1986). *Journal of the American Veterinary Medical Association* **193**, 1104-1108

90. AGUT, A., LAREDO, F. G., BELDA, E., SEVA, J. & SOLER, M. (2004) Left perinephric abscess associated with nephrolithiasis and bladder calculi in a bitch. *Veterinary Record* **154**, 562-565
91. DEMPSTER, A. G., DELAHUNT, B., MALTHUS, A. W. & WAKEFIELD, J. S. (2000) The histology and growth kinetics of canine renal oncocytoma. *Journal of Comparative Pathology* **123**, 294-298
92. HERNANDEZ, J. L., BESSO, J. G., RAULT, D. N., COHEN, A. H., GUIONNET, A., BEGON, D. & RUEL, Y. (2003) Emphysematous pyometra in a dog. *Veterinary Radiology and Ultrasound* **44**, 196-198
93. KIM, K. S. & KIM, O. (2005) Cystic endometrial hyperplasia and endometritis in a dog following prolonged treatment of medroxyprogesterone acetate. *Journal of Veterinary Science* **6**, 81-82
94. COLLINS, R. L., BIRCHARD, S. J., CHEW, D. J. & HEUTER, K. J. (1998) Surgical treatment of urate calculi in Dalmatians: 38 cases (1980-1995). *Journal of the American Veterinary Medical Association* **213**, 833-838
95. BROWN, C. A., JEONG, K. S., POPPENGA, R. H., PUSCHNER, B., MILLER, D. M., ELLIS, A. E., KANG, K. I., SUM, S., CISTOLA, A. M. & BROWN, S. A. (2007) Outbreaks of renal failure associated with melamine and cyanuric acid in dogs and cats in 2004 and 2007. *Journal of veterinary diagnostic investigation* **19**, 525-531
96. DiBARTOLA, S. P., TARR, M. J., PARKER, A. T., POWERS, J. D. & PULTZ, J. A. (1989) Clinicopathologic findings in dogs with renal amyloidosis: 59 cases (1976-1986). *Journal of the American Veterinary Medical Association* **195**, 358-364
97. EUBIG, P. A., BRADY, M. S., GWALTNEY-BRANT, S. M., KHAN, S. A., MAZZAFERRO, E. M. & MORROW, C. M. (2005) Acute renal failure in dogs after the ingestion of grapes or raisins: a retrospective evaluation of 43 dogs (1992-2002). *Journal of Veterinary Internal Medicine* **19**, 663-674
98. HUME, D. Z., DROBATZ, K. J. & HESS, R. S. (2006) Outcome of dogs with diabetic ketoacidosis: 127 dogs (1993-2003). *Journal of Veterinary Internal Medicine* **20**, 547-555
99. MELIAN, C. & PETERSON, M. E. (1996) Diagnosis and treatment of naturally occurring hypoadrenocorticism in 42 dogs. *Journal of Small Animal Practice* **37**, 268-275
100. PETERSON, M. E., KINTZER, P. P. & KASS, P. H. (1996) Pretreatment clinical and laboratory findings in dogs with hypoadrenocorticism: 225 cases (1979-1993). *Journal of the American Veterinary Medical Association* **208**, 85-91
101. SADEK, D. & SCHAEER, M. (1996) Atypical Addison's disease in the dog: a retrospective survey of 14 cases. *Journal of the American Animal Hospitals Association* **32**, 159-163
102. WILLARD, M. D., SCHALL, W. D., McCAW, D. E. & NACHREINER, R. F. (1982) Canine hypoadrenocorticism: report of 37 cases and review of 39 previously reported cases. *Journal of the American Veterinary Medical Association* **180**, 59-62
103. KLEITER, M., HIRT, R., KIRTZ, G. & DAY, M. J. (2001) Hypercalcaemia associated with chronic lymphocytic leukaemia in a Giant Schnauzer. *Australian Veterinary Journal* **79**, 335-338
104. RUSSELL, N. J., BOND, K. A., ROBERTSON, I. D., PARRY, B. W. & IRWIN, P. J. (2006) Primary hypoparathyroidism in dogs: a retrospective study of 17 cases. *Australian Veterinary Journal* **84**, 285-290
105. FORDYCE, H. H., CALLAN, M. B. & GIGER, U. (2000) Persistent cobalamin deficiency causing failure to thrive in a juvenile beagle. *Journal of Small Animal Practice* **41**, 407-410
106. VIRELLA, G., SLAPPENDEL, R. J. & GOUDSWAARD, J. (1977) Multiple myeloma, IgA cryoglobulinemia and serum hyperviscosity in a dog. *International Archives of Allergy and Applied Immunology* **55**, 537-541
107. KOWALCZYK, D. F. (1976) Lead poisoning in dogs at the University of Pennsylvania Veterinary Hospital. *Journal of the American Veterinary Medical Association* **168**, 428-432
108. THRALL, M. A., GRAUER, G. F. & MERO, K. N. (1984) Clinicopathologic findings in dogs and cats with ethylene glycol intoxication. *Journal of the American Veterinary Medical Association* **184**, 37-41
109. KAMMERER, M., SACHOT, E. & BLANCHOT, D. (2001) Ethanol toxicosis from the ingestion of rotten apples by a dog. *Veterinary and human toxicology* **43**, 349-350
110. STIDWORTHY, M. F., BLEAKLEY, J. S., CHEESEMAN, M. T. & KELLY, D. F. (1997) Chocolate poisoning in dogs. *Veterinary Record* **141**, 28-
111. FOSS, J. F., YUAN, C. S., ROIZEN, M. F. & GOLDBERG, L. I. (1998) Prevention of apomorphine- or cisplatin-induced emesis in the dog by a combination of methylalantrexone and morphine. *Cancer chemotherapy and pharmacology* **42**, 287-291
112. LEFEBVRE, R. A., WILLEMS, J. L. & BOGAERT, M. G. (1981) Gastric relaxation and vomiting by apomorphine, morphine and fentanyl in the conscious dog. *European Journal of Pharmacology* **69**, 139-145
113. UVNAS-WALLENSTEN, K. & GOINY, M. (1981) Effect of apomorphine on peripheral venous gastrin and insulin levels in conscious dogs. *Acta Physiologica Scandinavica* **112**, 155-160
114. SEDLACEK, H. S., RAMSEY, D. S., BOUCHER, J. F., EAGLESON, J. S., CONDER, G. A. & CLEMENCE, R. G. (2008) Comparative efficacy of maropitant and selected drugs in preventing emesis induced by centrally or peripherally acting emetogens in dogs. *Journal of Veterinary Pharmacology and Therapeutics* **31**, 533-537
115. KNAPP, D. W., RICHARDSON, R. C., BONNEY, P. L. & HAHN, K. (1988) Cisplatin therapy in 41 dogs with malignant tumors. *Journal of Veterinary Internal Medicine* **2**, 41-46
116. FUKUI, H. & YAMAMOTO, M. (1999) Methotrexate produces delayed emesis in dogs: a potential model of delayed emesis induced by chemotherapy. *European Journal of Pharmacology* **372**, 261-267
117. GYLYS, J. A., DORAN, K. M. & BUYNISKI, J. P. (1979) Antagonism of cisplatin induced emesis in the dog. *Research Communications in Chemical Pathology and Pharmacology* **23**, 61-68
118. OGLIVIE, G. K., MOORE, A. S. & CURTIS, C. R. (1989) Evaluation of cisplatin-induced emesis in dogs with malignant neoplasia: 115 cases (1984-1987). *Journal of the American Veterinary Medical Association* **195**, 1399-1403
119. DE LA PUENTE-REDONDO, V. A., TILT, N., ROWAN, T. G. & CLEMENCE, R. G. (2007) Efficacy of maropitant for treatment and prevention of emesis caused by intravenous infusion of cisplatin in dogs. *American Journal of Veterinary Research* **68**, 48-56
120. GUO, G. B., SCHMID, P. G. & ABBODD, F. M. (1982) Effect of digoxin and amino sugar cardiac glycoside (ASI-222) on plasma antidiuretic hormone activity. *Journal of Cardiovascular Pharmacology* **4**, 730-737
121. SENIOR, D. F., FEIST, E. H., STUART, L. B. & LOMBARD, C. W. (1991) Treatment of acute digoxin intoxication with digoxin immune fab (Ovine). *Journal of Veterinary Internal Medicine* **5**, 302-303
122. HOLLE, G. E., STEINBACH, E. & FORTH, W. (1992) Effects of erythromycin in the dog upper gastrointestinal tract. *American Journal of Physiology* **263**, G52-G59
123. ITOH, Z., SUZUKI, T., NAKAYA, M., INOUE, M. & MITSUHASHI, S. (1984) Gastrointestinal motor-stimulating activity of macrolide antibiotics and analysis of their side effects on the canine gut. *Antimicrobial Agents and Chemotherapy* **26**, 863-869
124. NAKAYOSHI, T., IZUMI, M., SHINKAI, S. & FUJITA, M. (1988) Comparative study on effects of 14- and 16-membered macrolides on gastrointestinal motility in unanaesthetized dogs. *Drugs under Experimental and Clinical Research* **14**, 319-325
125. OTTERSON, M. F. & SARNA, S. K. (1990) Gastrointestinal motor effects of erythromycin. *American Journal of Physiology* **259**, G355-G363
126. SCHULMAN, F. Y., RIBAS, J. L., CARPENTER, J. L., SISON, A. F. & LeCOUteur, R. A. (1992) Intracranial meningioma with pulmonary metastasis in three dogs. *Veterinary Quarterly* **29**, 196-202
127. ZAKI, F. A. & NAFE, L. A. (1980) Choroid plexus tumors in the dog. *Journal of the American Veterinary Medical Association* **176**, 328-330
128. BENCHAOUI, H. A., SIEDEK, E. M., DE LA PUENTE-REDONDO VA, TILT, N., ROWAN, T. G. & CLEMENCE, R. G. (2007) Efficacy of maropitant for preventing vomiting associated with motion sickness in dogs. *Veterinary Record* **161**, 444-447
129. CONDER, G. A., SEDLACEK, H. S., BOUCHER, J. F. & CLEMENCE, R. G. (2008) Efficacy and safety of maropitant, a selective neurokinin 1 receptor antagonist, in two randomized clinical trials for prevention of vomiting due to motion sickness in dogs. *Journal of Veterinary Pharmacology and Therapeutics* **31**, 528-532
130. WANG, S. C. & CHINN, H. I. (1954) Experimental motion sickness in dogs; functional importance of chemoceptive emetic trigger zone. *American Journal of Physiology* **178**, 111-116
131. STONEHEWER, J., MACKIN, A. J., TASKER, S., SIMPSON, J. W. & MAYHEW, I. G. (2000) Idiopathic phenobarbital-responsive hypersialosis in the dog: an unusual form of limbic epilepsy? *Journal of Small Animal Practice* **41**, 416-421
132. GAYNOR, A. R., SHOFER, F. S. & WASHABAU, R. J. (1997) Risk factors for acquired megaesophagus in dogs. *Journal of the American Veterinary Medical Association* **211**, 1406-1412
133. BROOKS, D. & WATSON, G. L. (1997) Omeprazole in a dog with gastrinoma. *Journal of Veterinary Internal Medicine* **11**, 379-381
134. CULBERT, L. A., MARINO, D. J., BAULE, R. M. & KNOX, V. W., III (1998) Complications associated with high-dose prednisolone sodium succinate therapy in dogs with neurological injury. *Journal of the American Animal Hospitals Association* **34**, 129-134
135. JOHN, D. J. (1975) Gastric mucosal damage by aspirin. *CRC critical reviews in toxicology* **3**, 317-344
136. MEDINGER, T. L., WILLIAMS, D. A. & BRUYETTE, D. S. (1993) Severe gastrointestinal tract hemorrhage in three dogs with hypoadrenocorticism. *Journal of the American Veterinary Medical Association* **202**, 1869-1872
137. PENNINGCK, D., MATZ, M. & TIDWELL, A. (1997) Ultrasonography of gastric ulceration in the dog. *Veterinary Radiology and Ultrasound* **38**, 308-312
138. PENNINGCK, D. G., MOORE, A. S. & GLIATTO, J. (1998) Ultrasonography of canine gastric epithelial neoplasia. *Veterinary Radiology and Ultrasound* **39**, 342-348
139. CARLIN, E. P., BOWMAN, D. D., SCARLETT, J. M., GARRETT, J. & LORENTZEN, L. (2006) Prevalence of Giardia in symptomatic dogs and cats throughout the United States as determined by the IDEXX SNAP Giardia test. *Veterinary therapeutics: research in applied veterinary medicine* **7**, 199-206
140. ESCUTENAIRE, S., ISAKSSON, M., RENSTROM, L. H., KLINGEBORN, B., BUONAVOGLIA, C., BERG, M., BELAK, S. & THOREN, P. (2007) Characterization of divergent and atypical canine coronaviruses from Sweden. *Archives of virology* **152**, 1507-1514
141. SASAKI, J., GORYO, M., ASAHINA, M., MAKARA, M., SHISHIDO, S. & OKADA, K. (1999) Hemorrhagic enteritis associated with Clostridium perfringens type A in a dog. *Journal of Veterinary Medicine and Science* **61**, 175-177
142. KULL, P. A., HESS, R. S., CRAIG, L. E., SAUNDERS, H. M. & WASHABAU, R. J. (2001) Clinical, clinicopathologic, radiographic, and ultrasonographic



- characteristics of intestinal lymphangiectasia in dogs: 17 cases (1996-1998). *Journal of the American Veterinary Medical Association* **219**, 197-202
143. NAYLOR, M. J., MONCKTON, R. P., LEHRBACH, P. R. & DEANE, E. M. (2001) Canine coronavirus in Australian dogs. *Australian Veterinary Journal* **79**, 116-119
144. MAAS, C. P., TER HAAR, G., VAN, D. G., I & KIRPENSTELJN, J. (2007) Reclassification of small intestinal and cecal smooth muscle tumors in 72 dogs: clinical, histologic, and immunohistochemical evaluation. *Veterinary Surgery* **36**, 302-313
145. MOHR, A. J., LEISEWITZ, A. L., JACOBSON, L. S., STEINER, J. M., RUAUX, C. G. & WILLIAMS, D. A. (2003) Effect of early enteral nutrition on intestinal permeability, intestinal protein loss, and outcome in dogs with severe parvoviral enteritis. *Journal of Veterinary Internal Medicine* **17**, 791-798
146. FRANSSON, B. A., KARLSTAM, E., BERGSTROM, A., LAGERSTEDT, A. S., PARK, J. S., EVANS, M. A. & RAGLE, C. A. (2004) C-reactive protein in the differentiation of pyometra from cystic endometrial hyperplasia/mucometra in dogs. *Journal of the American Animal Hospitals Association* **40**, 391-399
147. STALEY, E. C. & STALEY, E. E. (1995) Promethazine toxicity in a seven-month-old Doberman pinscher. *Veterinary and human toxicology* **37**, 243-244
148. PARADIS, M., ABBEY, L., BAKER, B., COYNE, M., HANNIGAN, M., JOFFE, D., PUKAY, B., TRETTEIN, A., WAISGLASS, S. & WELLS, L. (2001) Evaluation of the clinical efficacy of enrofloxacin (Zeniquin) tablets for the treatment of canine pyoderma: an open clinical trial. *Veterinary Dermatology* **12**, 163-169
149. RUSH, J. E. & KEENE, B. W. (1990) Metaproterenol intoxication in a dog. *Journal of the American Veterinary Medical Association* **197**, 1351-1353
150. WILSON, D. V., EVANS, A. T. & MILLER, R. (2005) Effects of preanesthetic administration of morphine on gastroesophageal reflux and regurgitation during anesthesia in dogs. *American Journal of Veterinary Research* **66**, 386-390
151. WILSON, D. V., TOM, E. A. & MAUER, W. A. (2007) Pre-anesthetic meperidine: associated vomiting and gastroesophageal reflux during the subsequent anesthetic in dogs. *Veterinary Anaesthesia and Analgesia* **34**, 15-22
152. WILLIAMSON, K. K., WILLARD, M. D., MCKENZIE, E. C., ROYER, C. M., PAYTON, M. E. & DAVIS, M. S. (2007) Efficacy of famotidine for the prevention of exercise-induced gastritis in racing Alaskan sled dogs. *Journal of Veterinary Internal Medicine* **21**, 924-927
153. ROBERTS, B. K., ARONSOHN, M. G., MOSES, B. L., BURK, R. L., TOLL, J. & WEEREN, F. R. (2000) Bufo marinus intoxication in dogs: 94 cases (1997-1998). *Journal of the American Veterinary Medical Association* **216**, 1941-1944
154. RENTON, J. P., BOYD, J. S. & HARVEY, M. J. (1993) Observations on the treatment and diagnosis of open pyometra in the bitch (*Canis familiaris*). *Journal of Reproduction and Fertility Supplement* **47**, 465-469
155. DECLERCQ, J. (2007) Suspected toxic shock-like syndrome in a dog with closed-cervix pyometra. *Veterinary Dermatology* **18**, 41-44
156. PENA, F. J., GINES, J. A., DUQUE, J., VIEITEZ, V., MARTINEZ-PEREZ, R., MADEJON, L., NUNEZ, M., I, MORAN, J. M. & FERNANDEZ-GARCIA, S. (2006) Endometrial adenocarcinoma and mucometra in a 6-year-old Alaska Malamute dog. *Reproduction in domestic animals* **41**, 189-190
157. RUPPERT, C., HARTMANN, K., FISCHER, A., HIRSCHBERGER, J., HAFNER, A. & SCHMIDT, P. (2000) Cervical neoplasia originating from the vagus nerve in a dog. *Journal of Small Animal Practice* **41**, 119-122
158. POZZI, A., SMEAK, D. D. & APER, R. (2006) Colonic seromuscular augmentation cystoplasty following subtotal cystectomy for treatment of bladder necrosis caused by bladder torsion in a dog. *Journal of the American Veterinary Medical Association* **229**, 235-239
159. SNYDER, D. M., STEFFEY, M. A., MEHLER, S. J., DROBATZ, K. J. & ARONSON, L. R. (2005) Diagnosis and surgical management of ureteral calculi in dogs: 16 cases (1990-2003). *New Zealand Veterinary Journal* **53**, 19-25
160. BOAG, A. K., COE, R. J., MARTINEZ, T. A. & HUGHES, D. (2005) Acid-base and electrolyte abnormalities in dogs with gastrointestinal foreign bodies. *Journal of Veterinary Internal Medicine* **19**, 816-821
161. YAM, P. S., JOHNSON, V. S., MARTINEAU, H. M., DICKIE, A. & SULLIVAN, M. (2002) Multicentric lymphoma with intestinal involvement in a dog. *Veterinary Radiology and Ultrasound* **43**, 138-143
162. FOX, L. E., ROSENTHAL, R. C., TWEDT, D. C., DUBIELZIG, R. R., MAC EWEN, E. G. & GRAUER, G. F. (1990) Plasma histamine and gastrin concentrations in 17 dogs with mast cell tumors. *Journal of Veterinary Internal Medicine* **4**, 242-246
163. LAURENDET, H., GOVENDIR, M., PORGES, W. L. & MALIK, R. (1998) Snoring and halitosis in a dog. *Australian Veterinary Journal* **76**, 245, 250-245, 251
164. COOKE, M. M. & GUILFORD, W. G. (1992) Salivary gland necrosis in a wire-haired fox terrier. *New Zealand Veterinary Journal* **40**, 69-72
165. SCHROEDER, H. & BERRY, W. L. (1998) Salivary gland necrosis in dogs: a retrospective study of 19 cases. *Journal of Small Animal Practice* **39**, 121-125
166. WIRHERLE, N., WIEMANN, A., OTTENJANN, M., LINZMANN, H., VAN DER, G. E., KOHN, B., GRUBER, A. D. & CLAUSEN, P. H. (2007) First case of canine peritoneal larval cestodosis caused by *Mesocostoides lineatus* in Germany. *Parasitology International* **56**, 317-320
167. VAN ISRAEL, N., KIRBY, B. M. & MUNRO, E. A. (2002) Septic peritonitis secondary to unilateral pyometra and ovarian bursal abscessation in a dog. *Journal of Small Animal Practice* **43**, 452-455
168. BUNCH, S. E., JOHNSON, S. E. & CULLEN, J. M. (2001) Idiopathic noncirrhotic portal hypertension in dogs: 33 cases (1982-1998). *Journal of the American Veterinary Medical Association* **218**, 392-399
169. POLLOCK, S. (1975) A case study: dysphagia from retained ingested string. *Veterinary medicine, small animal clinician* **70**, 833-835
170. CAPAK, D., SIMPRAGA, M., MATICIC, D., BALI, R. & JANOSKA, B. (2001) Incidence of foreign-body-induced ileus in dogs. *Berliner und Münchener tierärztliche Wochenschrift* **114**, 290-296
171. LOWE, A. D. (2004) Alimentary lymphosarcoma in a 4-year-old Labrador retriever. *Canadian Veterinary Journal* **45**, 610-612
172. PARTON, A. T., VOLK, S. W. & WEISSE, C. (2006) Gastric ulceration subsequent to partial invagination of the stomach in a dog with gastric dilatation-volvulus. *Journal of the American Veterinary Medical Association* **228**, 1895-1900
173. DERESZYNSKI, D. M., CENTER, S. A., RANDOLPH, J. F., BROOKS, M. B., HADDEN, A. G., PALYADA, K. S., McDONOUGH, S. P., MESSICK, J., STOKOL, T., BISCHOFF, K. L., GLUCKMAN, S. & SANDERS, S. Y. (2008) Clinical and clinicopathologic features of dogs that consumed foodborne hepatotoxic aflatoxins: 72 cases (2005-2006). *Journal of the American Veterinary Medical Association* **232**, 1329-1337
174. JACOBS, G., COLLINS-KELLY, L., LAPPIN, M. & TYLER, D. (1990) Lymphocytic-plasmacytic enteritis in 24 dogs. *Journal of Veterinary Internal Medicine* **4**, 45-53
175. LITTMAN, M. P., DAMBACH, D. M., VADEN, S. L. & GIGER, U. (2000) Familial protein-losing enteropathy and protein-losing nephropathy in Soft Coated Wheaten Terriers: 222 cases (1983-1997). *Journal of Veterinary Internal Medicine* **14**, 68-80
176. ADAMAMA-MORAITOU, K. K., PRASSINOS, N. N., PATSIKAS, M. N., PSYCHAS, V., TSIOLI, B. & RALLIS, T. S. (2004) Sclerosing encapsulating peritonitis in a dog with leishmaniasis. *Journal of Small Animal Practice* **45**, 117-121
177. CIENAVA, E. A., BARNHART, K. F., BROWN, R., MANSELL, J., DUNSTAN, R. & CREDILLE, K. (2004) Morphologic, immunohistochemical, and molecular characterization of hepatosplenic T-cell lymphoma in a dog. *Veterinary Clinical Pathology* **33**, 105-110
178. JOHNSON, C. S., FALES-WILLIAMS, A. J., REIMER, S. B., LOTSIKAS, P. J. & HAYNES, J. S. (2007) Fibrosing gastrointestinal leiomyositis as a cause of chronic intestinal pseudo-obstruction in an 8-month-old dog. *Veterinary Quarterly* **44**, 106-109
179. MUELLER, M. G., LUDWIG, L. L. & BARTON, L. J. (2001) Use of closed-suction drains to treat generalized peritonitis in dogs and cats: 40 cases (1997-1999). *Journal of the American Veterinary Medical Association* **219**, 789-794
180. VERGINE, M., POZZO, S., POGLIANI, E., RONDENA, M., ROCCABIANCA, P. & BERTAZZOLO, W. (2005) Common bile duct obstruction due to a duodenal gastrinoma in a dog. *Veterinary Journal* **170**, 141-143
181. COOPER, J. C. (2002) An endodermal cyst: the result of a congenital intestinal malformation. *Canadian Veterinary Journal* **43**, 712-714
182. MAULDIN, E. A., PALMEIRO, B. S., GOLDSCHMIDT, M. H. & MORRIS, D. O. (2006) Comparison of clinical history and dermatologic findings in 29 dogs with severe eosinophilic dermatitis: a retrospective analysis. *Veterinary Dermatology* **17**, 338-347
183. NEEL, J. A., TARIGO, J. & GRINDEM, C. B. (2006) Gallbladder aspirate from a dog. *Veterinary Clinical Pathology* **35**, 467-470
184. HUBBARD, K., SKELLY, B. J., MCKELVIE, J. & WOOD, J. L. (2007) Risk of vomiting and diarrhoea in dogs. *Veterinary Record* **161**, 755-757
185. GRAY, H. E., WEIGAND, C. M., COTTRILL, N. B., WILKINS, A. M. & MORGAN, R. V. (2003) Polycythemia vera in a dog presenting with uveitis. *Journal of the American Animal Hospitals Association* **39**, 355-360
186. MILLS, J. N., DAY, M. J., SHAW, S. E. & PENHALE, W. J. (1985) Autoimmune haemolytic anaemia in dogs. *Australian Veterinary Journal* **62**, 121-123
187. FIEBIGER, I. (1986) [Hypoglycemia in puppies and young dogs, especially in toy breeds]. *Tierärztliche Praxis* **14**, 515-524
188. STEINER, J. M., NEWMAN, S., XENOULIS, P., WOOLSEY, K., SUCHODOLSKI, J., WILLIAMS, D. & BARTON, L. (2008) Sensitivity of serum markers for pancreatitis in dogs with macroscopic evidence of pancreatitis. *Veterinary therapeutics: research in applied veterinary medicine* **9**, 263-273
189. HUGHES, A. M., NELSON, R. W., FAMULA, T. R. & BANNASCH, D. L. (2007) Clinical features and heritability of hypoadrenocorticism in Nova Scotia Duck Tolling Retrievers: 25 cases (1994-2006). *Journal of the American Veterinary Medical Association* **231**, 407-412
190. YILMAZ, Z. & SENTURK, S. (2007) Characterisation of lipid profiles in dogs with parvoviral enteritis. *Journal of Small Animal Practice* **48**, 643-650
191. WORLEY, D. R., HOTTINGER, H. A. & LAWRENCE, H. J. (2004) Surgical management of gallbladder mucoceles in dogs: 22 cases (1999-2003). *Journal of the American Veterinary Medical Association* **225**, 1418-1422
192. GODSHALK, C. P., ROUSH, J. K., FINGLAND, R. B., SIKKEMA, D. & VORHIES, M. W. (1992) Gastric



- perforation associated with administration of ibuprofen in a dog. *Journal of the American Veterinary Medical Association* **201**, 1734-1736
193. LAMB, W. A. & FRANCE, M. P. (1994) Chronic intestinal pseudo-obstruction in a dog. *Australian Veterinary Journal* **71**, 84-86
 194. IRAUSQUIN, R. A., SCAVELLI, T. D., CORTI, L., STEFANACCI, J. D., DEMARCO, J., FLOOD, S. & ROHRBACH, B. W. (2008) Comparative evaluation of the liver in dogs with a splenic mass by using ultrasonography and contrast-enhanced computed tomography. *Canadian Veterinary Journal* **49**, 46-52
 195. CLIFFORD, C. A., PRETORIUS, E. S., WEISSE, C., SORENMO, K. U., DROBATZ, K. J., SIEGELMAN, E. S. & SOLOMON, J. A. (2004) Magnetic resonance imaging of focal splenic and hepatic lesions in the dog. *Journal of Veterinary Internal Medicine* **18**, 330-338
 196. GAROSI, L. S., DENNIS, R., PLATT, S. R., CORLETTI, F., DE LAHUNTA, A. & JAKOBS, C. (2003) Thiamine deficiency in a dog: clinical, clinicopathologic, and magnetic resonance imaging findings. *Journal of Veterinary Internal Medicine* **17**, 719-723
 197. SINGH, M., THOMPSON, M., SULLIVAN, N. & CHILD, G. (2005) Thiamine deficiency in dogs due to the feeding of sulphite preserved meat. *Australian Veterinary Journal* **83**, 412-417
 198. GUALTIERI, M. (1996) Gastrointestinal polyps in small animals. *European Journal of Comparative Gastroenterology* **1**, 1-11
 199. MAZAKI-TOVI, M., BANETH, G., AROCH, I., HARRUS, S., KASS, P. H., BEN ARI, T., ZUR, G., AIZENBERG, I., BARK, H. & LAVY, E. (2002) Canine spirocerosis: clinical, diagnostic, pathologic, and epidemiologic characteristics. *Veterinary Parasitology* **107**, 235-250
 200. DRANE, D. P., HAMILTON, R. C. & COX, J. C. (1994) Evaluation of a novel diagnostic test for canine parvovirus. *Veterinary Microbiology* **41**, 293-302
 201. CARPENTER, D. O., BRIGGS, D. B. & STROMINGER, N. (1984) Peptide-induced emesis in dogs. *Behavioural Brain Research* **11**, 277-281
 202. COHEN, B. M. & LIPINSKI, J. F. (1986) In vivo potencies of antipsychotic drugs in blocking alpha 1 noradrenergic and dopamine D2 receptors: implications for drug mechanisms of action. *Life Sciences* **39**, 2571-2580
 203. VALVERDE, A., CANTWELL, S., HERNANDEZ, J. & BROTHERRSON, C. (2004) Effects of acepromazine on the incidence of vomiting associated with opioid administration in dogs. *Veterinary Anaesthesia and Analgesia* **31**, 40-45
 204. ALPHIN, R. S., PROAKIS, A. G., LEONARD, C. A., SMITH, W. L., DANNENBURG, W. N., KINNIER, W. J., JOHNSON, D. N., SANCILIO, L. F. & WARD, J. W. (1986) Antagonism of cisplatin-induced emesis by metoclopramide and dazopride through enhancement of gastric motility. *Digestive Diseases and Sciences* **31**, 524-529
 205. BURGER, D. M., WIESTNER, T., HUBLER, M., BINDER, H., KEISER, M. & ARNOLD, S. (2006) Effect of anticholinergics (atropine, glycopyrrolate) and prokinetics (metoclopramide, cisapride) on gastric motility in beagles and labrador retrievers. *Journal of Veterinary Medicine, Physiology, pathology, clinical medicine* **53**, 97-107
 206. DE LA PUENTE-REDONDO, V. A., SIEDEK, E. M., BENCHAOUI, H. A., TILT, N., ROWAN, T. G. & CLEMENCE, R. G. (2007) The anti-emetic efficacy of maropitant (Cerenia) in the treatment of ongoing emesis caused by a wide range of underlying clinical aetiologies in canine patients in Europe. *Journal of Small Animal Practice* **48**, 93-98
 207. HALL, J. A., SOLIE, T. N., SEIM, H. B. & TWEED, D. C. (1996) Effect of metoclopramide on fed-state gastric myoelectric and motor activity in dogs. *American Journal of Veterinary Research* **57**, 1616-1622
 208. MITCHELL, W. C. & VENABLE, D. D. (1985) Effects of metoclopramide on detrusor function. *Journal of urology* **134**, 791-794
 209. ORIHATA, M. & SARNA, S. K. (1994) Contractile mechanisms of action of gastroprokinetic agents: cisapride, metoclopramide, and domperidone. *Am J Physiol*; 266(4 Pt 1): G665-76. *American Journal of Physiology* **266**, G665-676
 210. QIN, X. Y., PILOT, M. A., THOMPSON, H. & SCOTT, M. (1993) Effects of cholinceptor and 5-hydroxytryptamine3 receptor antagonism on erythromycin-induced canine intestinal motility disruption and emesis. *British Journal of Pharmacology* **108**, 44-49
 211. THIES, P., JANISCH, H. D., VON KLEIST, D. H., WOLF, K. U. & HAMPEL, K. E. (1990) [Metoclopramide antagonizes dopamine-induced inhibition of lower esophageal sphincter pressure in the awake beagle]. *Gastroenterologische Journal* **50**, 91-96
 212. WILSON, D. V., EVANS, A. T. & MAUER, W. A. (2006) Influence of metoclopramide on gastroesophageal reflux in anesthetized dogs. *American Journal of Veterinary Research* **67**, 26-31
 213. FINN, A. L. (1992) Toxicity and side effects of ondansetron. *Semin-Oncol.* **19**, 53-60
 214. FITZPATRICK, L. R., LAMBERT, R. M., PENDLEY, C. E., MARTIN, G. E., BOSTWICK, J. S., GESSNER, G. W., AIREY, J. E., YOUSSEFYEH, R. D., PENDLETON, R. G. & DECKTOR, D. L. (1990) RG 12915: a potent 5-hydroxytryptamine-3 antagonist that is an orally effective inhibitor of cytotoxic drug-induced emesis in the ferret and dog. *Journal of Pharmacology and Experimental Therapeutics* **254**, 450-455
 215. GOMEZ-DE-SEGURA, I. A., GRANDE, A. G. & DE MIGUEL, E. (1998) Antiemetic effects of Leri-setron in radiation-induced emesis in the dog. *Acta Oncologica* **37**, 759-763
 216. LIN, H. C., NEEVEL, C. & CHEN, J. H. (2004) Slowing intestinal transit by PYY depends on serotonergic and opioid pathways. *American journal of physiology. Gastrointestinal and liver physiology* **286**, G558-G563
 217. MIZUMOTO, A., MURAMATSU, S., YAMADA, T. & ITOH, Z. (1997) Effect of nitric oxide synthase inhibition on plasma motilin release in fasted dogs. *Regulatory Peptides* **71**, 9-14
 218. SAGRADA, A., TURCONI, M., BONALI, P., SCHIANTARELLI, P., MICHELETTI, R., MONTAGNA, E., NICOLA, M., ALGATE, D. R., RIMOLDI, E. M. & DONETTI, A. (1991) Antiemetic activity of the new 5-HT3 antagonist DAU 6215 in animal models of cancer chemotherapy and radiation. *Cancer chemotherapy and pharmacology* **28**, 470-474
 219. SHARMA, S. S., KOCHUPILLAI, V., GUPTA, S. K., SETH, S. D. & GUPTA, Y. K. (1997) Antiemetic efficacy of ginger (Zingiber officinale) against cisplatin-induced emesis in dogs. *Journal of Ethnopharmacology* **57**, 93-96
 220. TOPAL, A., KAYA, M. & GUL, N. (2005) Ondansetron and granisetron in the prophylaxis of nausea induced by cisplatin in dogs. *Acta Veterinaria Brno* **74**, 111-116
 221. VEASEY, S. C., CHACHKES, J., FENIK, P. & HENDRICKS, J. C. (2001) The effects of ondansetron on sleep-disordered breathing in the English bulldog. *Sleep* **24**, 155-160
 222. YOSHIDA, N., MIZUMOTO, A., IWANAGA, Y. & ITOH, Z. (1991) Effects of 5-hydroxytryptamine 3 receptor antagonists on gastrointestinal motor activity in conscious dogs. *Journal of Pharmacology and Experimental Therapeutics* **256**, 272-278
 223. VAIL, D. M., RODABAUGH, H. S. & CONDER, G. A. (2007) Efficacy of injectable maropitant (Cerenia™) in a randomized clinical trial for prevention and treatment of cisplatin-induced emesis in dogs presented as veterinary patients. *Veterinary and comparative oncology* **5**, 38-46
 224. PFIZER ANIMAL HEALTH-DATA ON FILE.
 225. JORDAN, K., KASPER, C. & SCHMOLL, H. J. (2005) Chemotherapy-induced nausea and vomiting: current and new standards in the antiemetic prophylaxis and treatment. *European Journal of Cancer* **41**, 199-205